

**mpMRI IN DIAGNOSIS AND  
STAGING OF PROSTATE CANCER**  
**Current Status and Future Directions**

G. Villeirs



Genitourinary Radiology  
**Ghent University Hospital, Belgium**





**DIAGNOSIS**

**mp**  
**MRI**



**mp**  
**MRI**

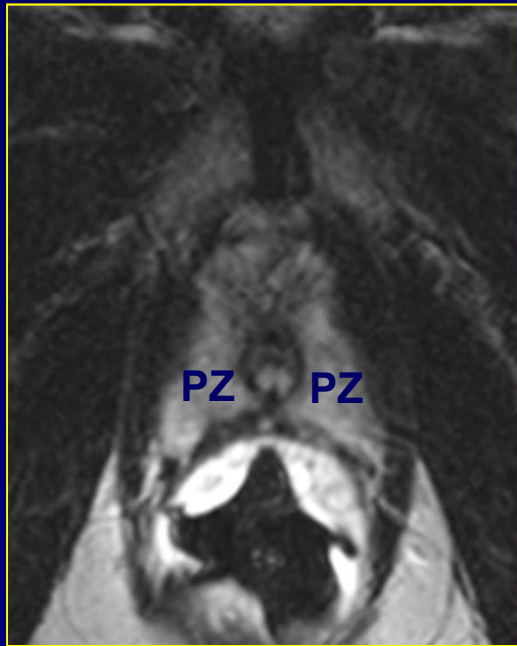
A Venn diagram consisting of three overlapping circles. The circles are arranged in a triangular pattern, with each circle overlapping the other two. The central area where all three circles overlap contains the text "mp MRI" in a bold, white, sans-serif font. The circles themselves are drawn with a thin, light-colored line. The background is a solid, dark blue color.

**T2W**

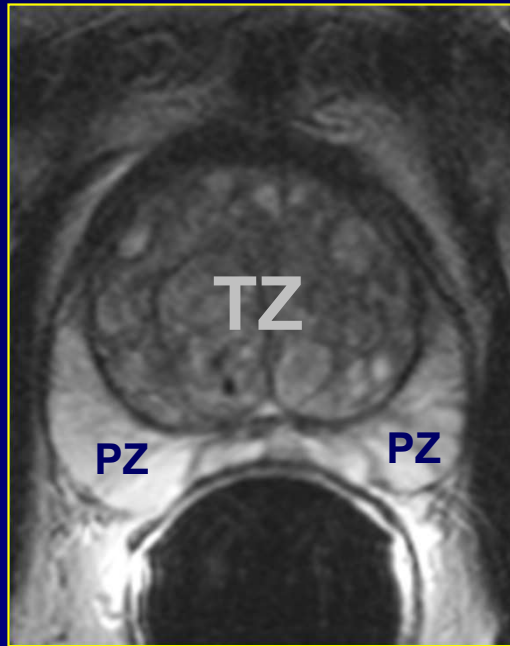
**mp  
MRI**

# T2-weighted MRI

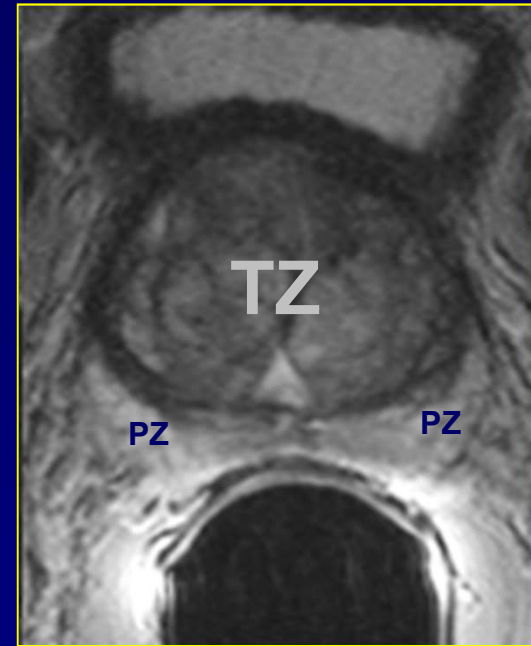
## Anatomy



Prostatic Apex



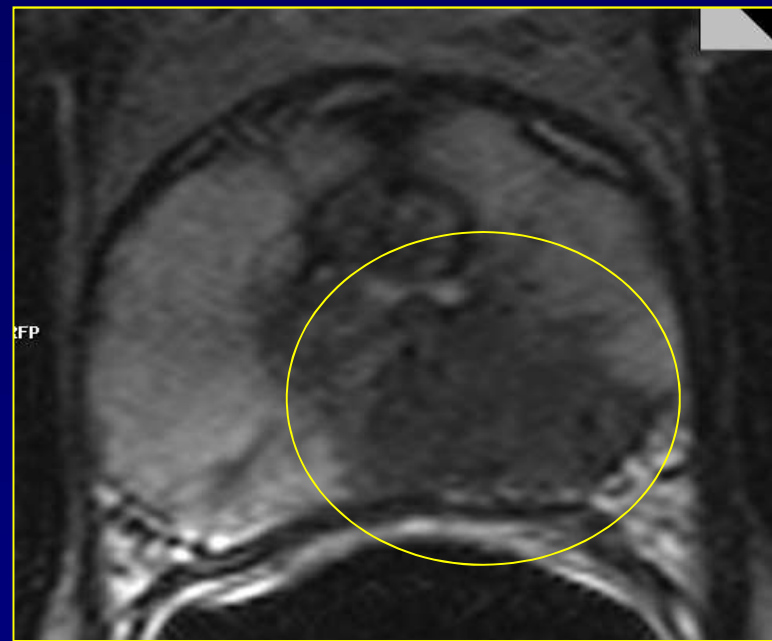
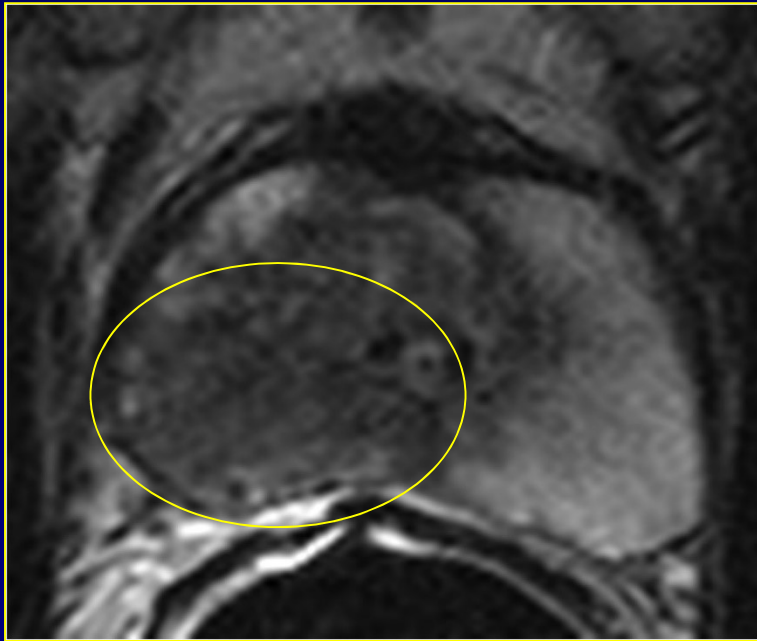
Midprostate



Prostatic Base

# T2-weighted MRI

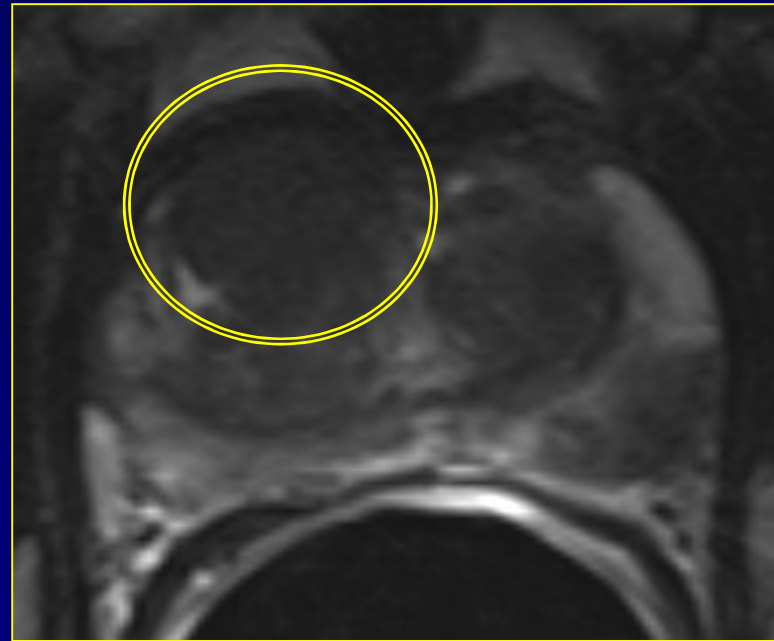
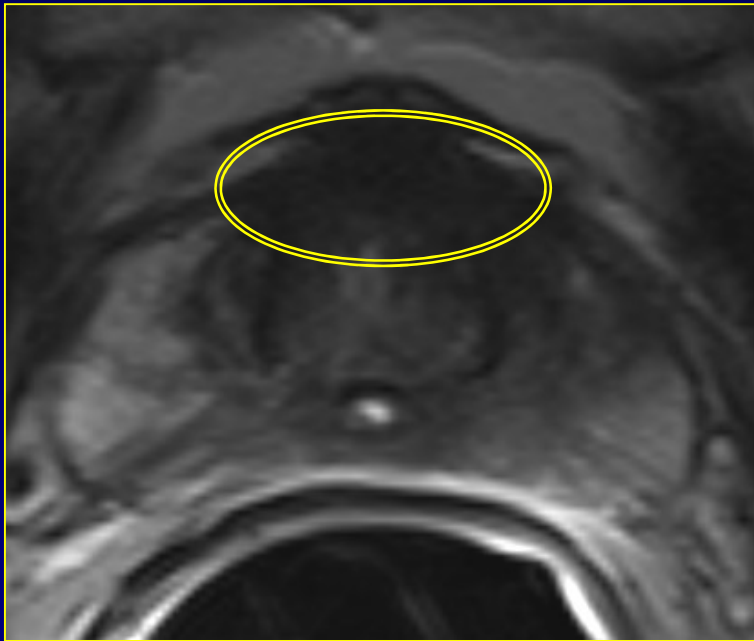
## Peripheral zone cancer



Low signal intensity area

# T2-weighted MRI

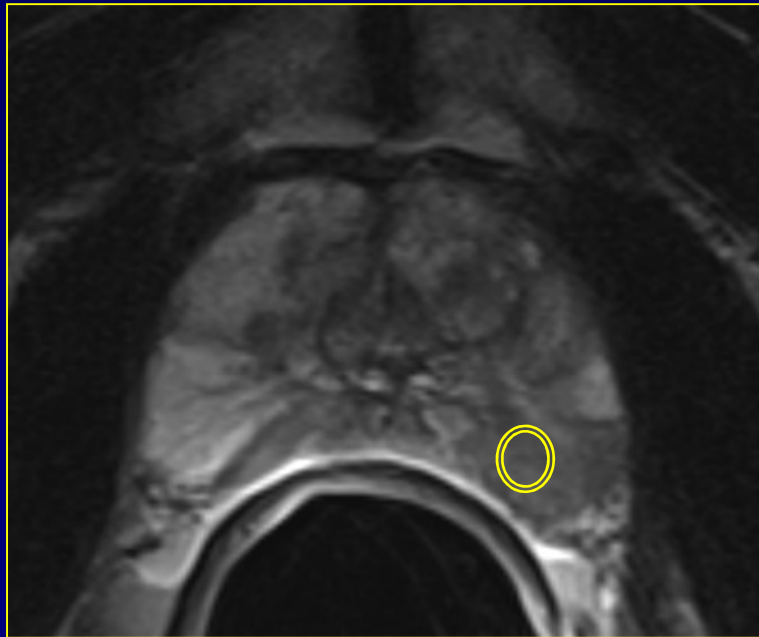
## Transition zone cancer



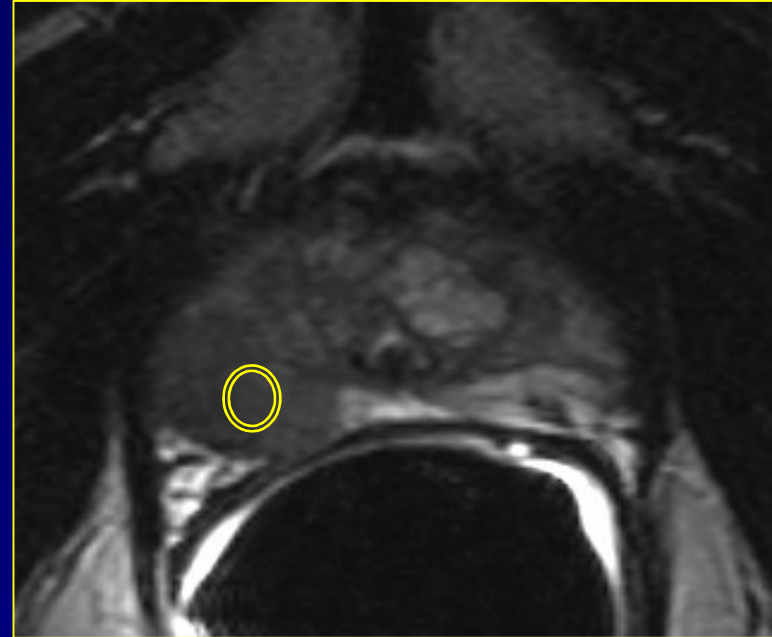
Area of uniform signal intensity decrease

# T2-weighted MRI

## Assessment of aggressiveness



Gleason 3+3




Gleason 4+5

Wang, Radiology 2008;246:168  
May, Invest Radiol 2019;54:146

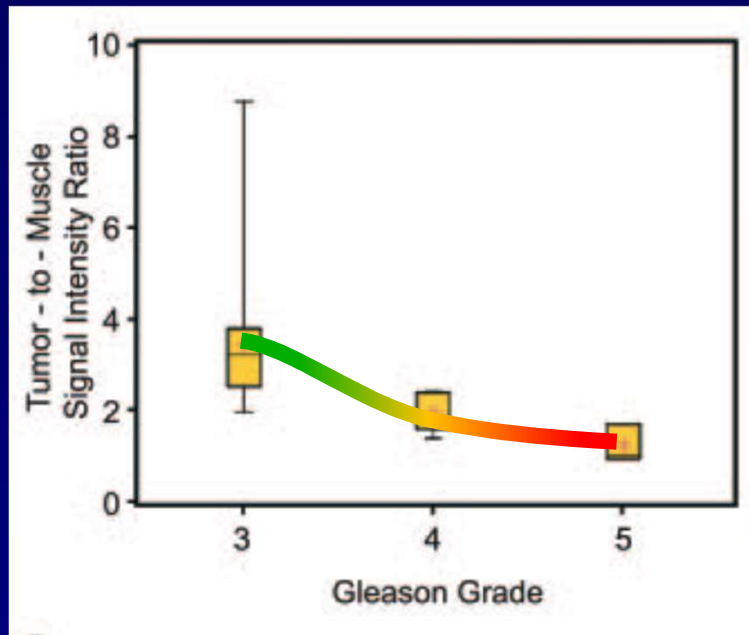
# T2-weighted MRI

## Assessment of aggressiveness

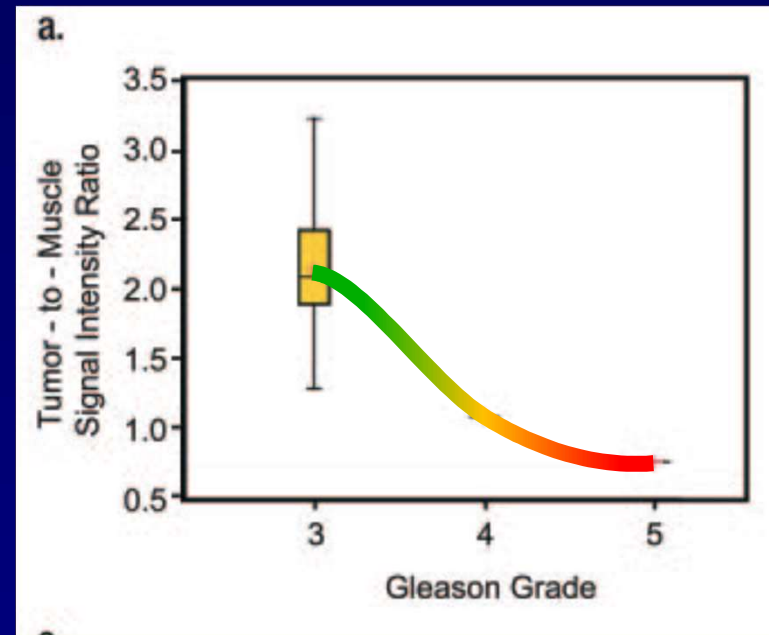


# T2-weighted MRI

## Assessment of aggressiveness



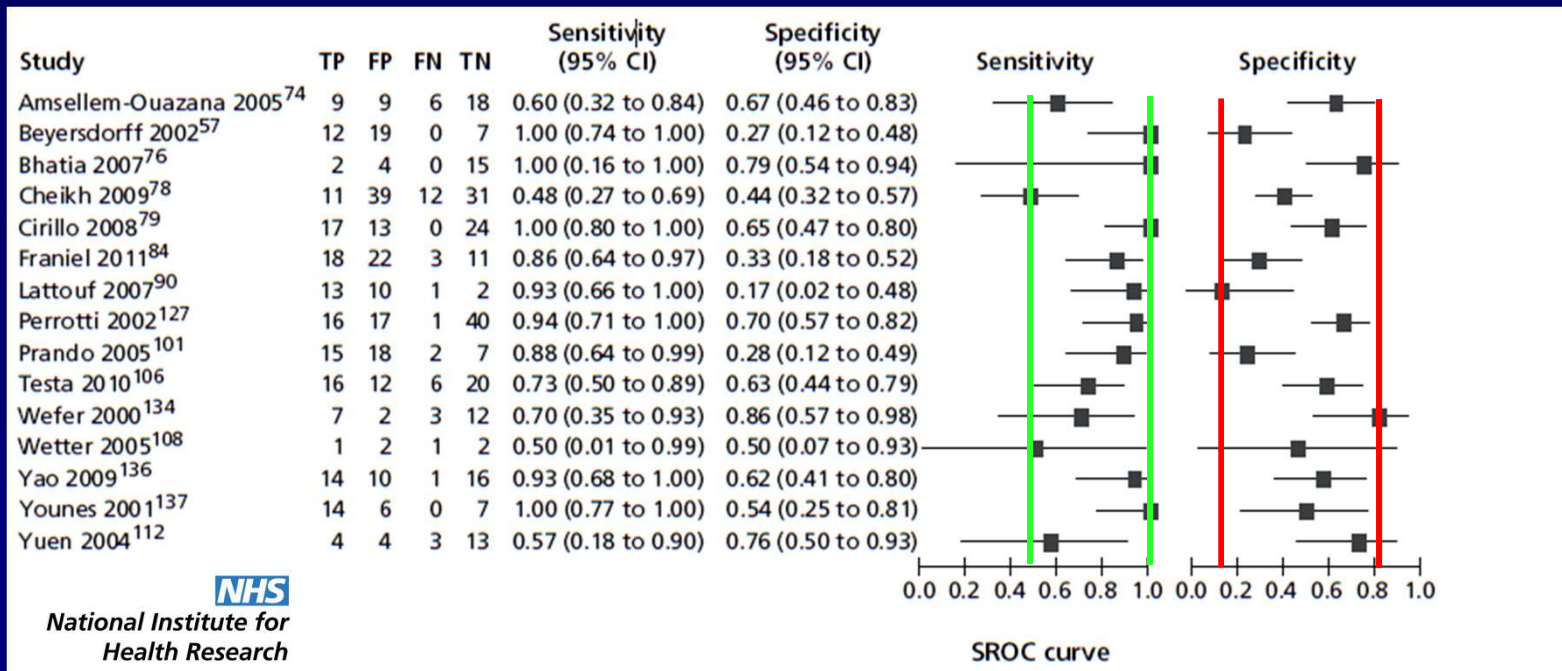
Peripheral Zone



Transition Zone

# T2-weighted MRI

## Diagnostic value



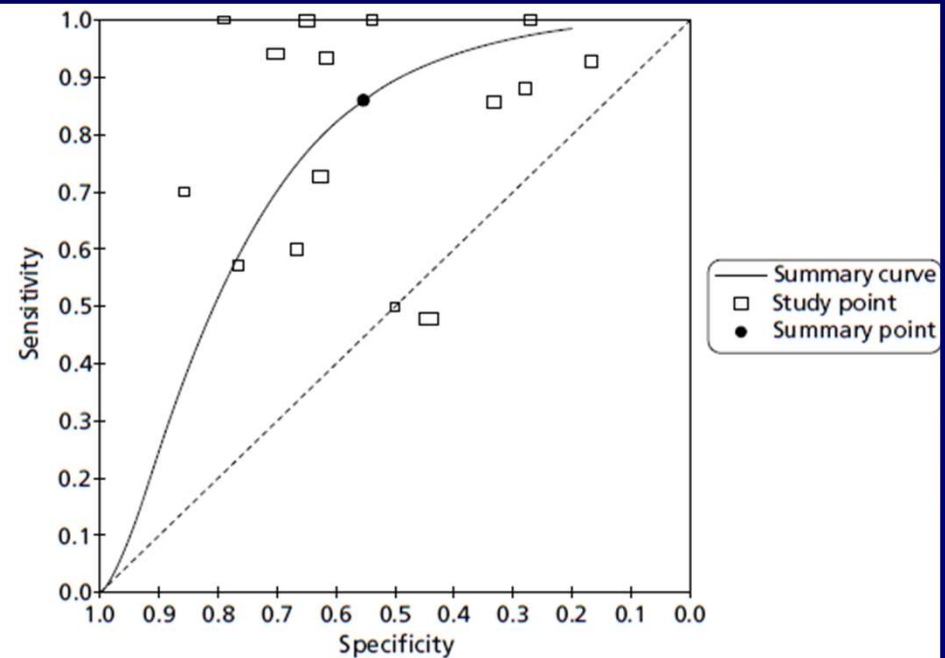
**NHS**

National Institute for  
Health Research

# T2-weighted MRI

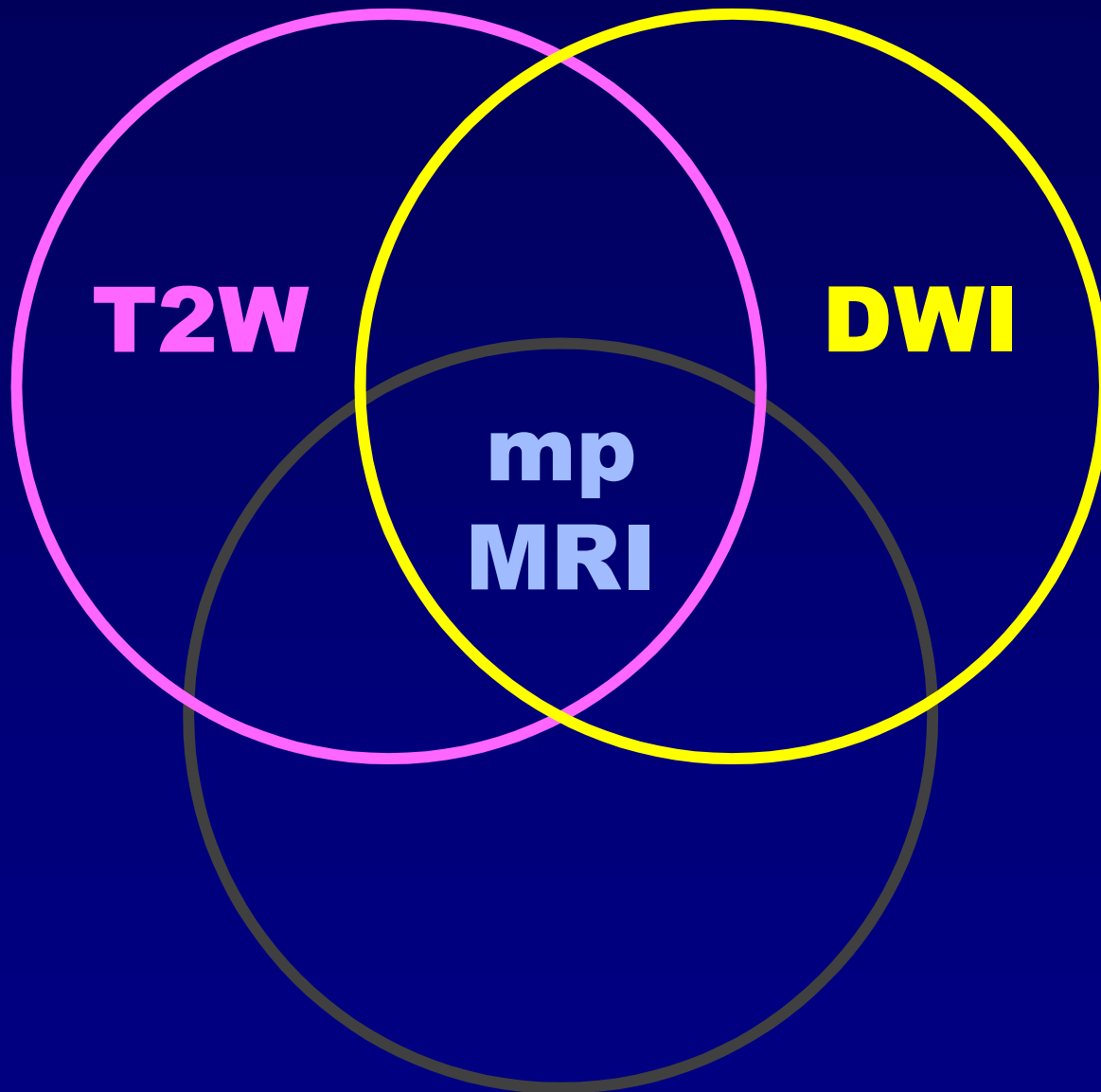
## Diagnostic value

Pooled estimates (95% CI)	
Sensitivity	0.86 (0.74 to 0.93)
Specificity	0.55 (0.44 to 0.66)
DOR	7.64 (3.37 to 17.30)
LR+	1.93 (1.50 to 2.47)
LR-	0.25 (0.13 to 0.49)



**T2W**

**mp  
MRI**



**T2W**

**DWI**

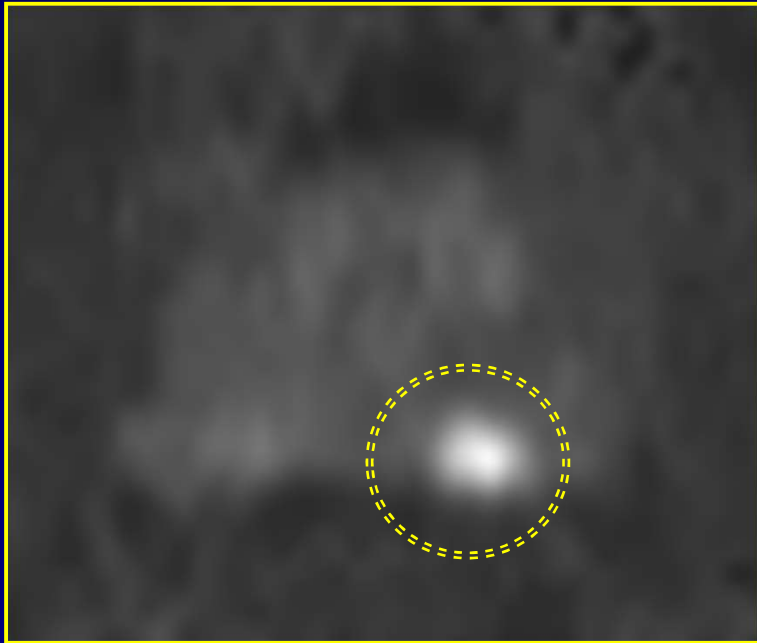
**mp  
MRI**

# Diffusion-Weighted Imaging Phenotype

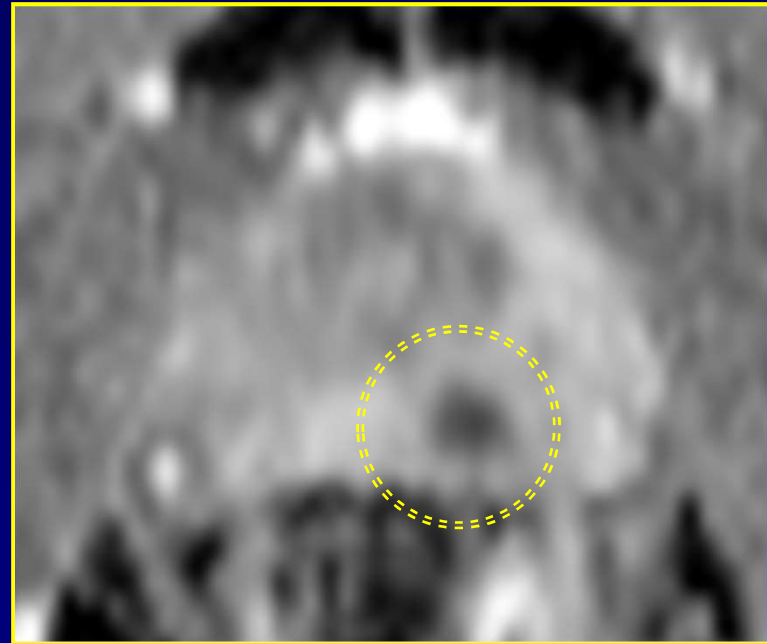
- Principle = INHIBITION OF WATER DIFFUSION
  - No inhibition in normal tissue (fluid filled ducts, low/intermediate cellular density)
  - Much inhibition in tumour lesions (vast tumoral sheaths, high cellular density)

# Diffusion-Weighted Imaging

## Peripheral zone cancer



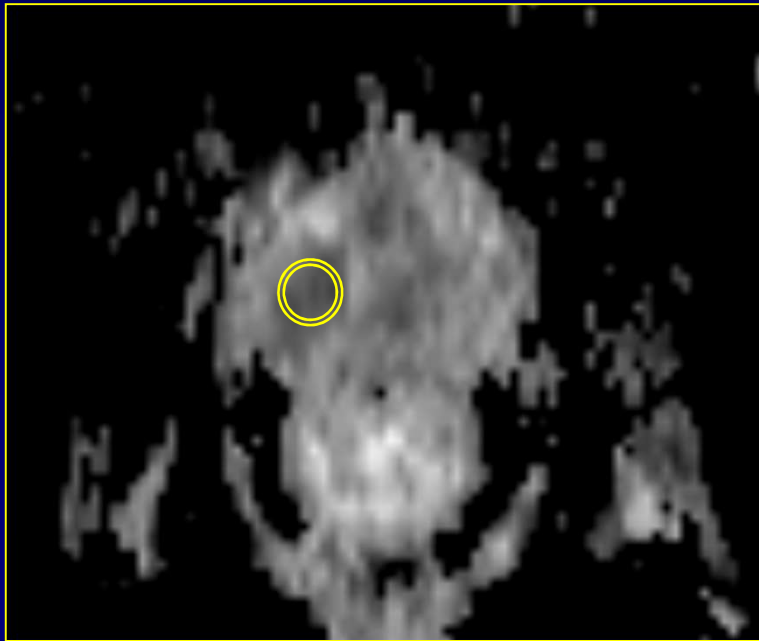
b1400



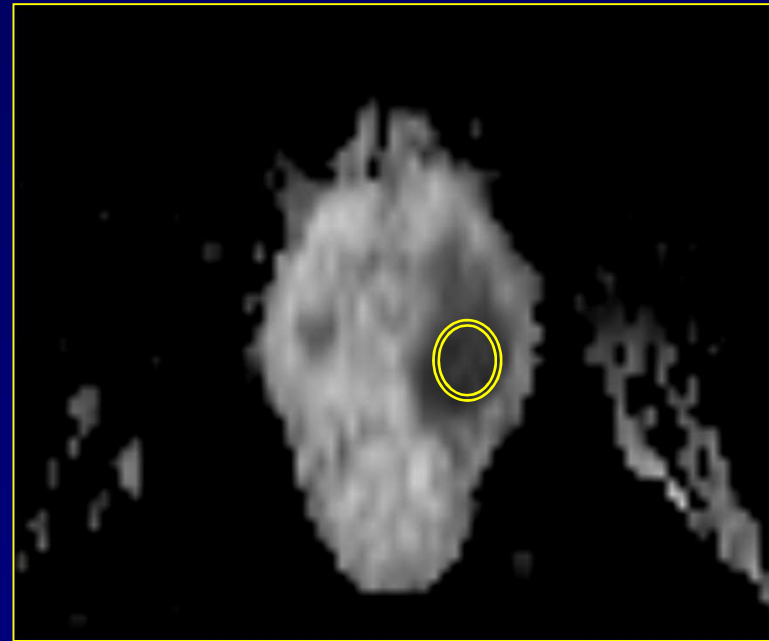
ADC

# Diffusion-Weighted Imaging

## Assessment of aggressiveness



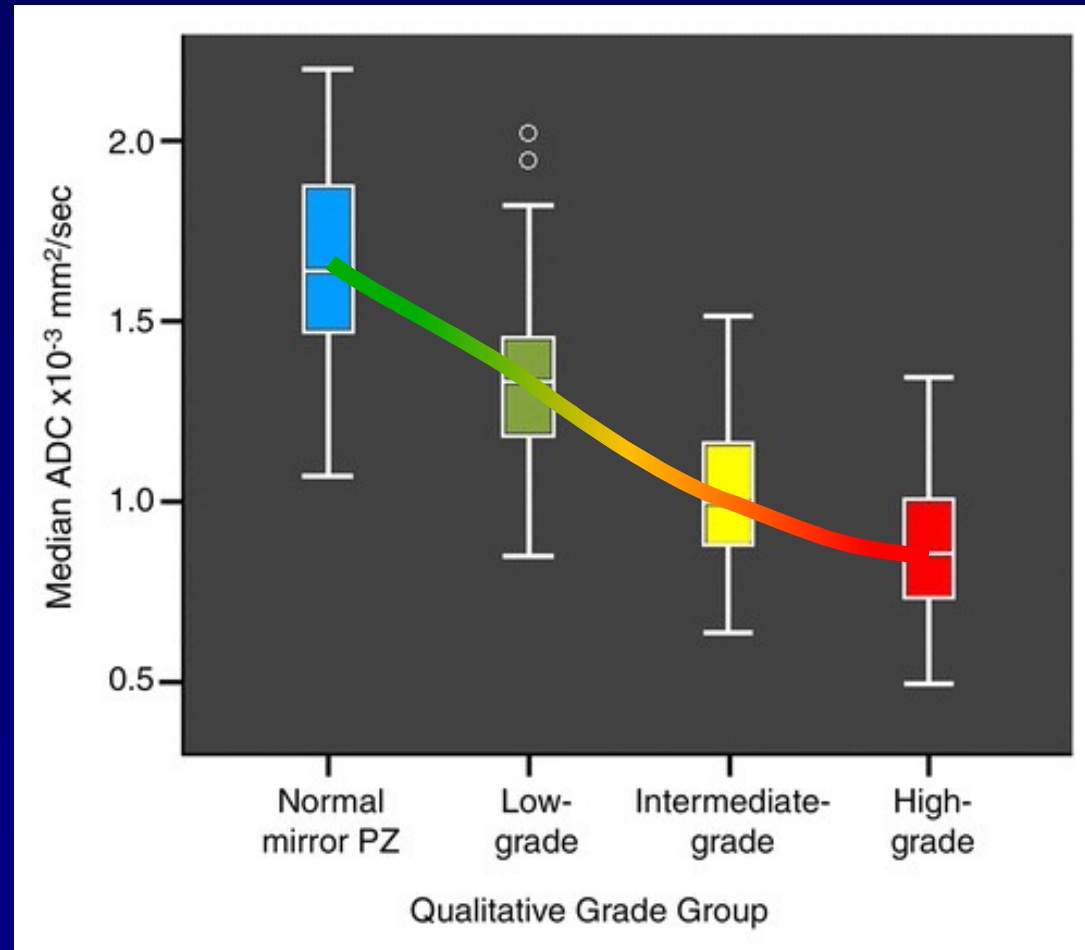
ADC 762  
Gleason 3+4



ADC 518  
Gleason 5+4

# Diffusion-Weighted Imaging

## Assessment of aggressiveness



\*Hambrock, Eur Urol. 2012 Jan;61(1):177-84

# Diffusion-Weighted Imaging

## Assessment of aggressiveness

- ADC-value inversely correlates with tumor aggressiveness (Gleason score)\*
- best correlation in peripheral zone\*\*

\*Hambrock, Eur Urol. 2012 Jan;61(1):177-84

Caivano, Cancer Invest 2013;31:625-629

Kitajima, Eur J Radiol. 2013 Aug;82(8):1219-26

Hötker, AJR Am J Roentgenol 2016;206:756

Wu, Diagn Interv Imaging 2017;98:63

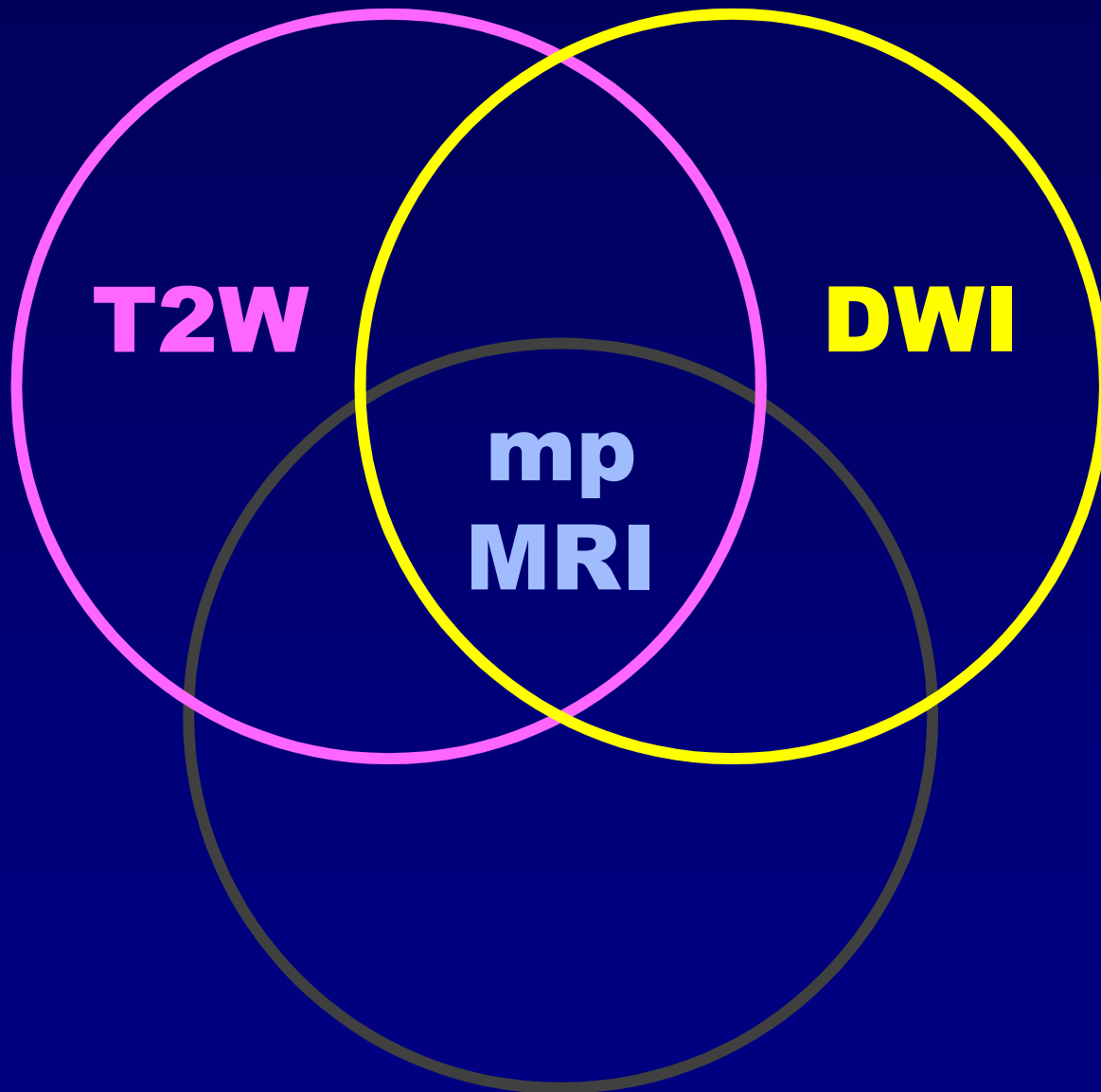
\*\*Kobus, Radiology. 2012 Nov;265(2):457-67

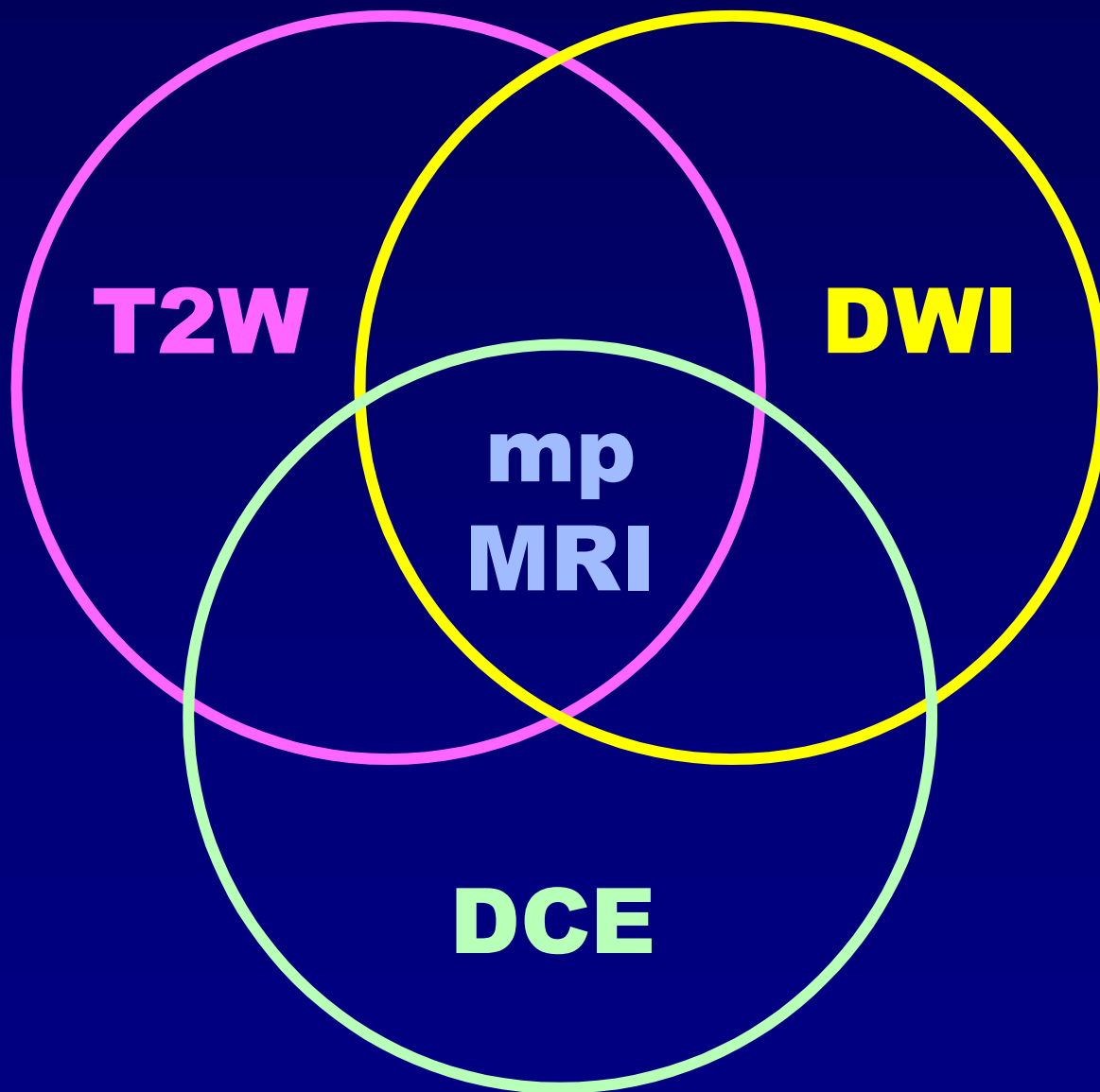
# Diffusion-Weighted Imaging

## Diagnostic value

- Diagnostic value of high b-value DWI ( $b > 1000$ ) for detection\*:
  - 80% pooled sensitivity
  - 92% pooled specificity

\*Woo, AJR 2018;210:91



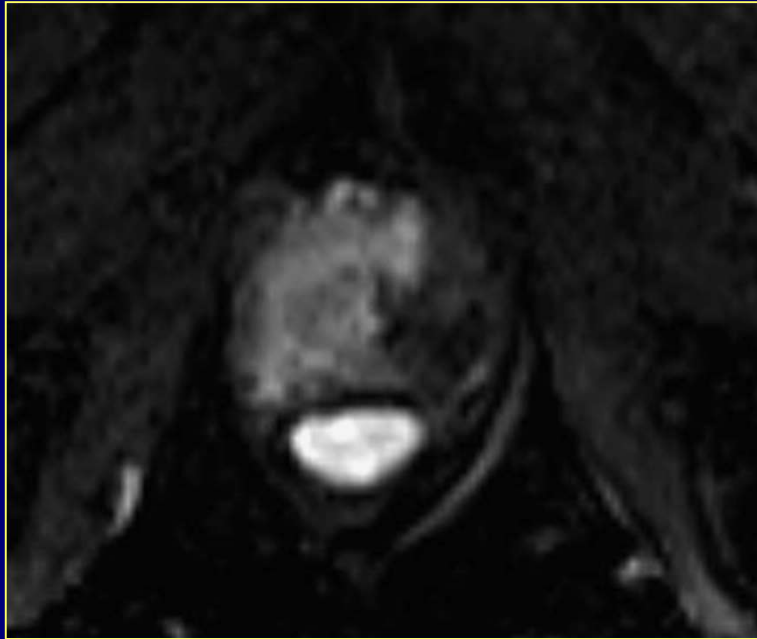


# Dynamic Contrast-Enhanced MRI Phenotype

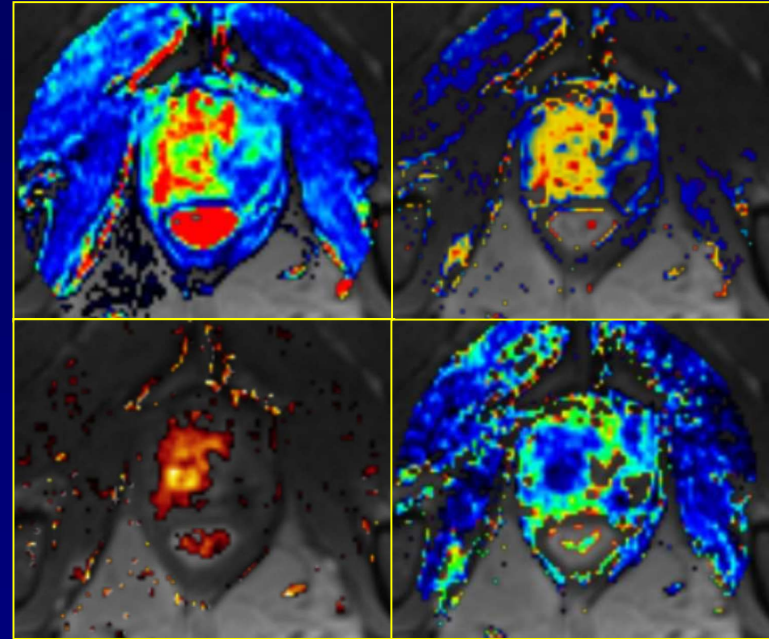
- Principle = DEMONSTRATION OF NEOANGIOGENESIS

# Dynamic Contrast-Enhanced MRI

## Phenotype



Subtraction image

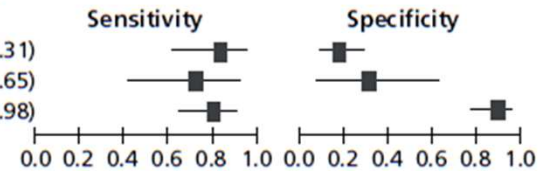


Tofts Model  
(iAUC,  $K^{\text{trans}}$ ,  $v_e$ ,  $k_{\text{ep}}$ )

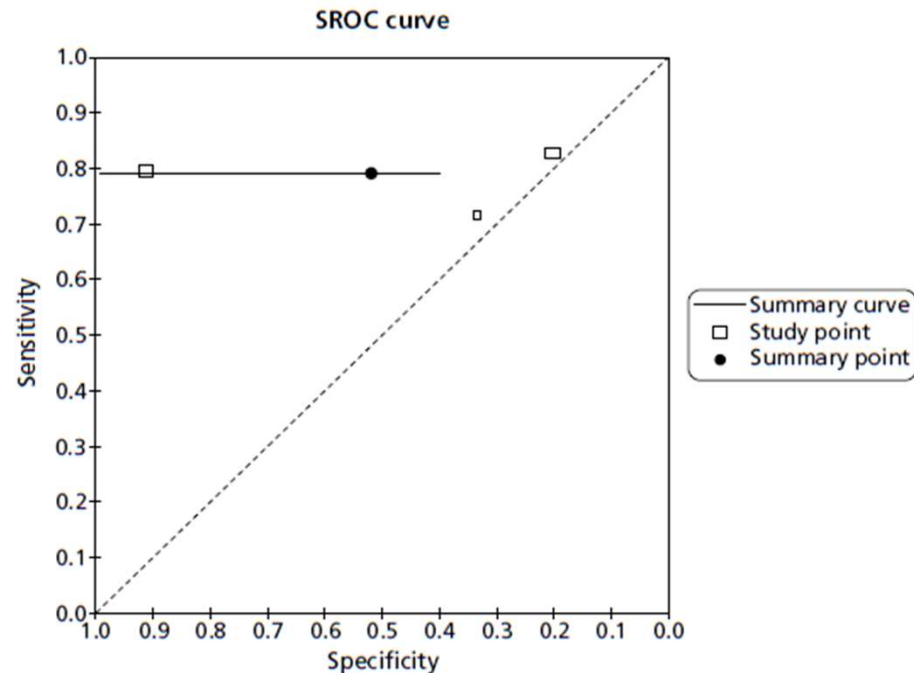
# Dynamic Contrast-Enhanced MRI

## Diagnostic value

Study	TP	FP	FN	TN	Sensitivity (95% CI)	Specificity (95% CI)
Cheikh 2009 <sup>78</sup>	19	56	4	14	0.83 (0.61 to 0.95)	0.20 (0.11 to 0.31)
Lattouf 2007 <sup>90</sup>	10	8	4	4	0.71 (0.42 to 0.92)	0.33 (0.10 to 0.65)
Sciarra 2010 <sup>105</sup>	35	4	9	42	0.80 (0.65 to 0.90)	0.91 (0.79 to 0.98)



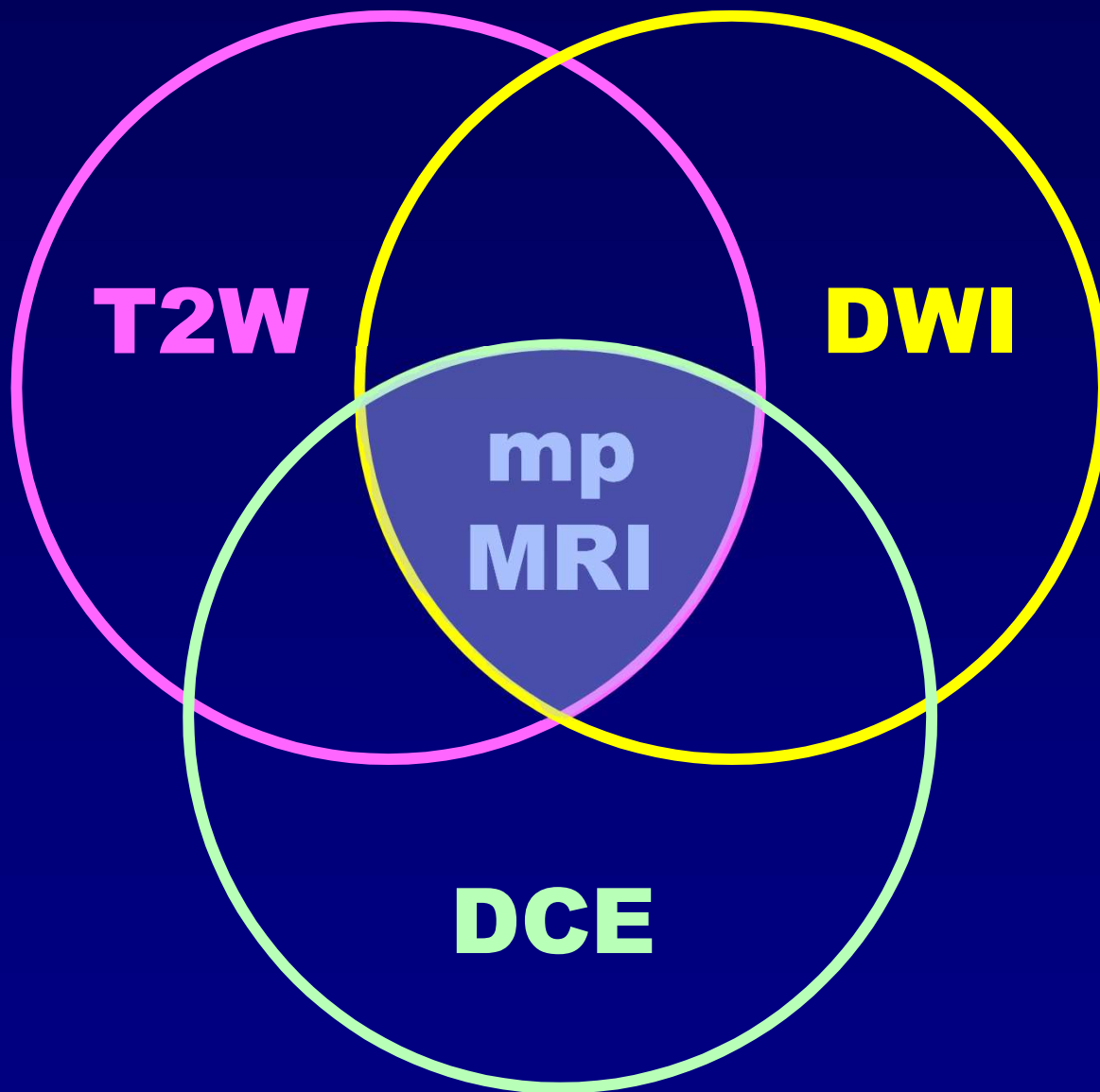
Pooled estimates (95% CI)	
Sensitivity	0.79 (0.69 to 0.87)
Specificity	0.52 (0.14 to 0.88)
DOR	4.05 (0.55 to 29.64)
LR+	1.64 (0.60 to 4.46)
LR-	0.41 (0.15 to 1.12)



# Dynamic Contrast-Enhanced MRI

## Use

- False positive enhancement in TZ (benign prostatic hyperplasia) yielding lower specificity
- Use DCE for peripheral zone only





## ESUR prostate MR guidelines 2012

Jelle O. Barentsz • Jonathan Richenberg •  
Richard Clements • Peter Choyke • Sadhna Verma •  
Geert Villeirs • Olivier Rouviere • Vibeke Logager •  
Jurgen J. Fütterer

Received: 16 October 2011 / Revised: 23 November 2011 / Accepted: 2 December 2011 / Published online: 10 February 2012  
© The Author(s) 2012. This article is published with open access at Springerlink.com

**Abstract** The aim was to develop clinical guidelines for multi-parametric MRI of the prostate by a group of prostate MRI experts from the European Society of Urogenital Radiology (ESUR), based on literature evidence and consensus expert opinion. True evidence-based guidelines could not be formulated, but a compromise, reflected by “minimal” and


### *Key Points*

- *This report provides guidelines for magnetic resonance imaging (MRI) in prostate cancer.*
- *Clinical indications, and minimal and optimal imaging acquisition protocols are provided.*
- *A structured reporting system (PI-RADS) is described.*

# PI-RADS™

Prostate Imaging – Reporting  
and Data System

2015  
version 2




**ACR**<sup>®</sup>  
AMERICAN COLLEGE OF  
RADIOLOGY  
QUALITY IS OUR IMAGE

# PI-RADS<sup>®</sup>

Prostate Imaging – Reporting  
and Data System

2019  
Version 2.1



**ACR<sup>®</sup>**  
AMERICAN COLLEGE OF  
RADIOLOGY  
QUALITY IS OUR IMAGE

# Multiparametric MRI

PI-RADS™ v2

## SECTION IV: MULTIPARAMETRIC MRI (MPMRI)

### A. T<sub>1</sub>-Weighted (T<sub>1</sub>W) and T<sub>2</sub>-Weighted (T<sub>2</sub>W)

Both T<sub>1</sub>W and T<sub>2</sub>W sequences should be obtained for all prostate MR exams. T<sub>1</sub>W images are used primarily to determine the presence of hemorrhage within the prostate and seminal vesicles and to delineate the outline of the gland. T<sub>1</sub>W images may also be useful for detection of nodal and skeletal metastases, especially following intravenous administration of a gadolinium-based contrast agent (GBCA).

T<sub>2</sub>W images are used to discern prostatic zonal anatomy, assess abnormalities within the gland, and to evaluate for seminal vesicle invasion, EPE, and nodal involvement.

On T<sub>2</sub>W images, clinically significant cancers in the PZ usually appear as round or ill-defined hypointense focal lesions. However, this appearance is not specific and can be seen in various conditions such as prostatitis, hemorrhage, glandular atrophy, benign hyperplasia, biopsy related scars, and after therapy (hormone, ablation, etc.).

The T<sub>2</sub>W features of TZ tumors include non-circumscribed homogeneous, moderately hypointense lesions ("erased charcoal" or "smudgy fingerprint" appearance), spiculated margins, lenticular shape, absence of a complete hypointense capsule, and invasion of the urethral sphincter and anterior fibromuscular stroma. The more features present, the higher the likelihood of a clinically significant TZ cancer.

TZ cancers may be difficult to identify on T<sub>2</sub>W images since the TZ is often composed of variable amounts of glandular (T<sub>2</sub>-hyperintense) and stromal (T<sub>2</sub>-hypointense) tissue intermixed with each other, thus demonstrating heterogeneous signal intensity. Areas where benign stromal elements predominate may mimic or obscure clinically significant cancer.

Both PZ and TZ cancers may extend across anatomical boundaries. Invasive behavior is noted when there is extension within the gland (i.e. across regional parts of the prostate), into the seminal vesicles, or outside the gland (EPE).

#### 1. Technical Specifications

##### T<sub>2</sub>W

Multiplanar (axial, coronal, and sagittal) T<sub>2</sub>W images are usually obtained with 2D RARE (rapid acquisition with relaxation enhancement) pulse sequences, more commonly known as fast-spin-echo (FSE) or turbo-spin-echo (TSE). In order to avoid blurring, excessive echo train lengths should be avoided.

- Slice thickness: 3mm, no gap. Locations should be the same as those used for DWI and DCE
- FOV: generally 12-20 cm to encompass the entire prostate gland and seminal vesicles
- In plane dimension:  $\leq 0.7$ mm (phase) x  $\leq 0.4$ mm (frequency)

3D axial acquisitions may be used as an adjunct to 2D acquisitions. If acquired using isotropic voxels, 3D acquisitions may be particularly useful for visualizing detailed anatomy and

# Multiparametric MRI

PI-RADS™ v2

## SECTION IV: MULTIPARAMETRIC MRI (MPMRI)

### A. T<sub>1</sub>-Weighted (T<sub>1</sub>W) and T<sub>2</sub>-Weighted (T<sub>2</sub>W)

Both T<sub>1</sub>W and T<sub>2</sub>W sequences should be obtained for all prostate MR exams. T<sub>1</sub>W images are used primarily to determine the presence of hemorrhage within the prostate and seminal vesicles and to delineate the outline of the gland. T<sub>1</sub>W images may also be useful for detection of nodal and skeletal metastases, especially following intravenous administration of a gadolinium-based contrast agent (GBCA).

T<sub>2</sub>W images are used to discern prostatic zonal anatomy, assess abnormalities within the gland, and to evaluate for seminal vesicle invasion, EPE, and nodal involvement.

On T<sub>2</sub>W images, clinically significant cancers in the PZ usually appear as round or ill-defined hypointense focal lesions. However, this appearance is not specific and can be seen in various conditions such as prostatitis, hemorrhage, glandular atrophy, benign hyperplasia, biopsy-related scars, and after therapy (hormone, ablation, etc.).

The T<sub>2</sub>W features of TZ tumors include non-circumscribed homogeneous, moderately hypointense lesions ("erased charcoal" or "smudgy fingerprint" appearance), spiculated margins, lenticular shape, absence of a complete hypointense capsule, and invasion of the urethral sphincter and anterior fibromuscular stroma. The more features present, the higher the likelihood of a clinically significant TZ cancer.

TZ cancers may be difficult to identify on T<sub>2</sub>W images since the TZ is often composed of variable amounts of glandular (T<sub>2</sub>-hyperintense) and stromal (T<sub>2</sub>-hypointense) tissue intermixed with each other, thus demonstrating heterogeneous signal intensity. Areas where benign stromal elements predominate may mimic or obscure clinically significant cancer.

Both PZ and TZ cancers may extend across anatomical boundaries. Invasive behavior is noted when there is extension within the gland (i.e. across regional parts of the prostate), into the seminal vesicles, or outside the gland (EPE).

#### 1. Technical Specifications

##### T<sub>2</sub>W

Multiplanar (axial, coronal, and sagittal) T<sub>2</sub>W images are usually obtained with 2D RARE (rapid acquisition with relaxation enhancement) pulse sequences, more commonly known as fast-spin-echo (FSE) or turbo-spin-echo (TSE). In order to avoid blurring, excessive echo train lengths should be avoided.

- Slice thickness: 3mm, no gap. Locations should be the same as those used for DWI and DCE
- FOV: generally 12-20 cm to encompass the entire prostate gland and seminal vesicles
- In plane dimension:  $\leq 0.7$ mm (phase) x  $\leq 0.4$ mm (frequency)

3D axial acquisitions may be used as an adjunct to 2D acquisitions. If acquired using isotropic voxels, 3D acquisitions may be particularly useful for visualizing detailed anatomy and

# Multiparametric MRI

## PI-RADS™ v2

distinguishing between genuine lesions and partial volume averaging effects. However, the soft tissue contrast is not identical and in some cases may be inferior to that seen on 2D T2W images, and the in-plane resolution may be lower than their 2D counterpart.

### T1W

Axial T1W images of the prostate may be obtained with or without fat suppression using spin echo or gradient echo sequences. Locations should be the same as those used for DWI and DCE, although lower spatial resolution compared to T2W may be used to decrease acquisition time or increase anatomic coverage.

### 2. PI-RADS Assessment for T2W

Score	Peripheral Zone (PZ)
1	Uniform hyperintense signal intensity (normal)
2	Linear or wedge-shaped hypointensity or diffuse mild hypointensity, usually indistinct margin
3	Heterogeneous signal intensity or non-circumscribed, rounded, moderate hypointensity  Includes others that do not qualify as 2, 4, or 5
4	Circumscribed, homogenous moderate hypointense focus/mass confined to prostate and <1.5 cm in greatest dimension
5	Same as 4 but ≥1.5cm in greatest dimension or definite extraprostatic extension/invasive behavior

Score	Transition Zone (TZ)
1	Homogeneous intermediate signal intensity (normal)
2	Circumscribed hypointense or heterogeneous encapsulated nodule(s) (BPH)
3	Heterogeneous signal intensity with obscured margins  Includes others that do not qualify as 2, 4, or 5
4	Lenticular or non-circumscribed, homogeneous, moderately hypointense, and <1.5 cm in greatest dimension
5	Same as 4, but ≥1.5cm in greatest dimension or definite extraprostatic extension/invasive behavior

# Multiparametric MRI

PI-RADS™ v2

distinguishing between genuine lesions and partial volume averaging effects. However, the soft tissue contrast is not identical and in some cases may be inferior to that seen on 2D T2W images, and the in-plane resolution may be lower than their 2D counterpart.

## T1W

Axial T1W images of the prostate may be obtained with or without fat suppression using spin echo or gradient echo sequences. Locations should be the same as those used for DWI and DCE, although lower spatial resolution compared to T2W may be used to decrease acquisition time or increase anatomic coverage.

## 2. PI-RADS Assessment for T2W

Score	Peripheral Zone (PZ)
1	Uniform hyperintense signal intensity (normal)
2	Linear or wedge-shaped hypointensity or diffuse mild hypointensity, usually indistinct margin
3	Heterogeneous signal intensity or non-circumscribed, rounded, moderate hypointensity  Includes others that do not qualify as 2, 4, or 5
4	Circumscribed, homogenous moderate hypointense focus/mass confined to prostate and <1.5 cm in greatest dimension
5	Same as 4 but ≥1.5cm in greatest dimension or definite extraprostatic extension/invasive behavior

Score	Transition Zone (TZ)
1	Homogeneous intermediate signal intensity (normal)
2	Circumscribed hypointense or heterogeneous encapsulated nodule(s) (BPH)
3	Heterogeneous signal intensity with obscured margins  Includes others that do not qualify as 2, 4, or 5
4	Lenticular or non-circumscribed, homogeneous, moderately hypointense, and <1.5 cm in greatest dimension
5	Same as 4, but ≥1.5cm in greatest dimension or definite extraprostatic extension/invasive behavior

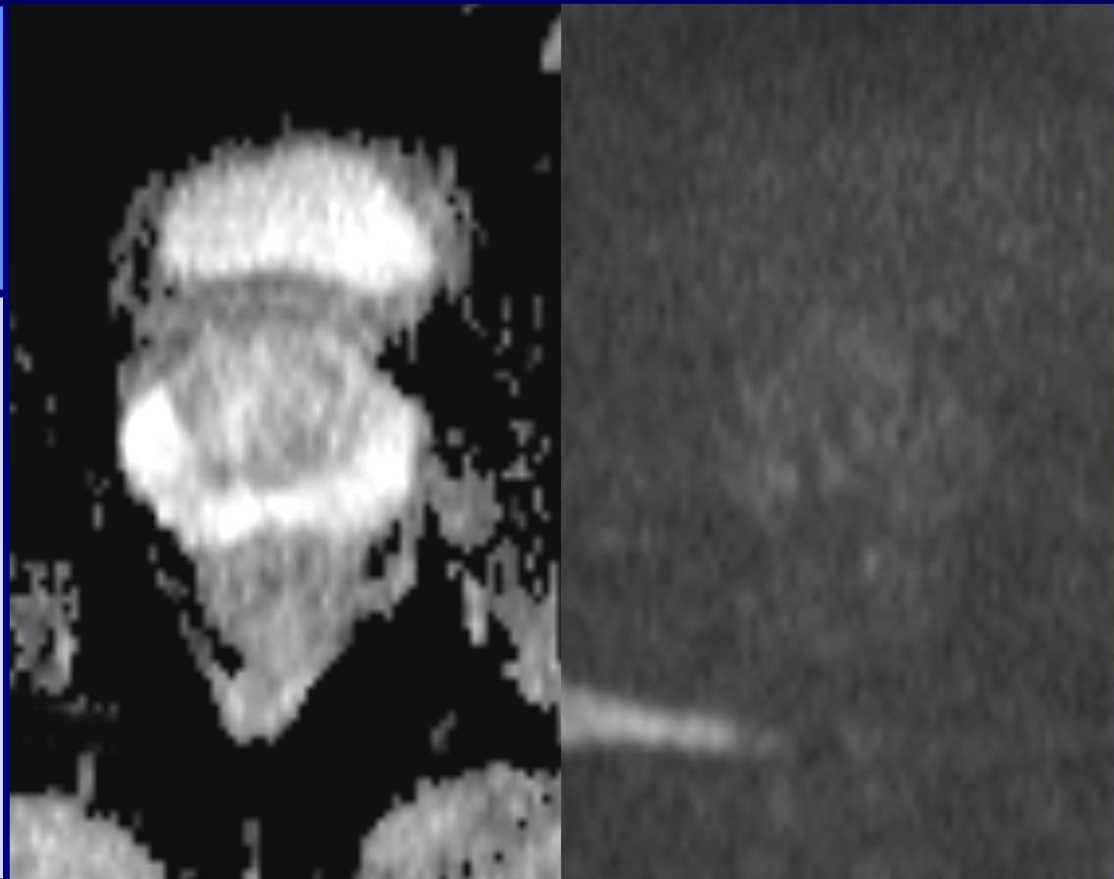
# Multiparametric MRI

- PIRADSv2
  - Assessment and reporting
    - PZ: dominance of DWI
    - TZ: dominance of T2
    - DCE: problem solving in peripheral zone
    - MRSI: not used

# DWI in PERIPHERAL ZONE

## PIRADS 1

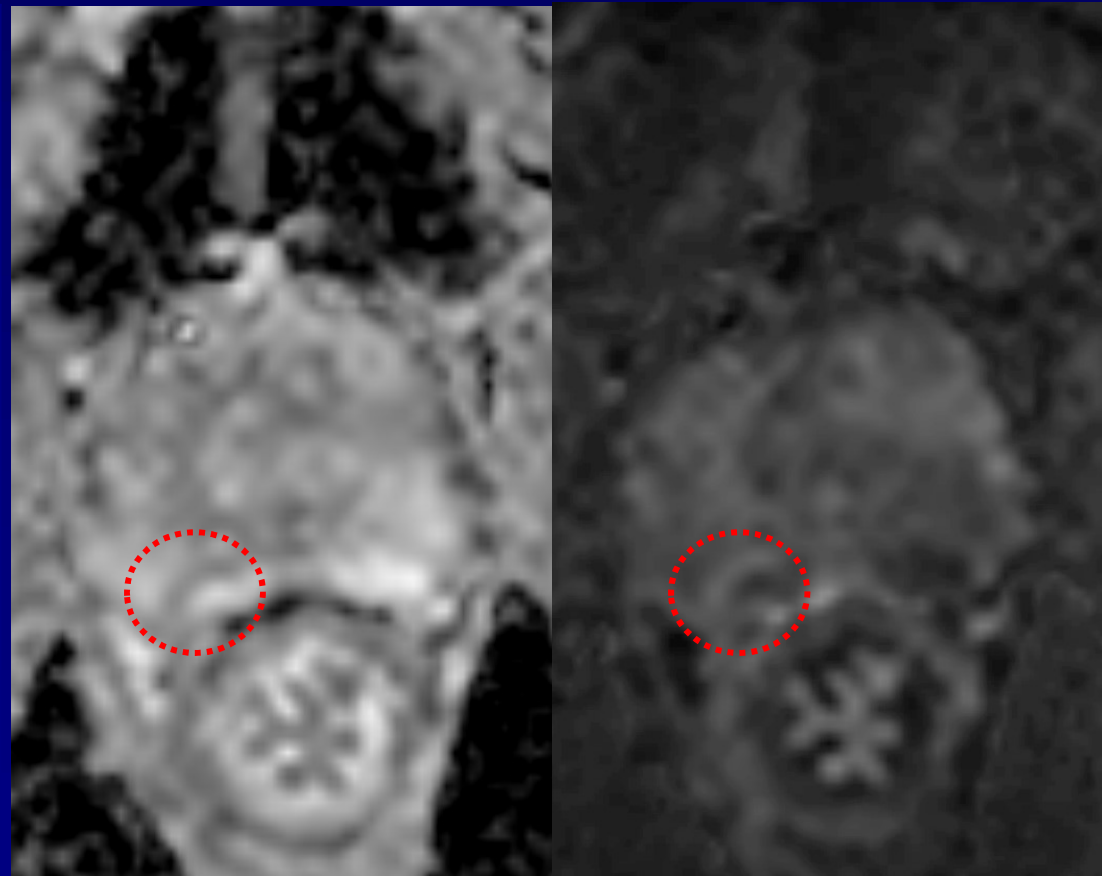
No abnormality  
on ADC and high  
b-value DWI



# DWI in PERIPHERAL ZONE

## PIRADS 2

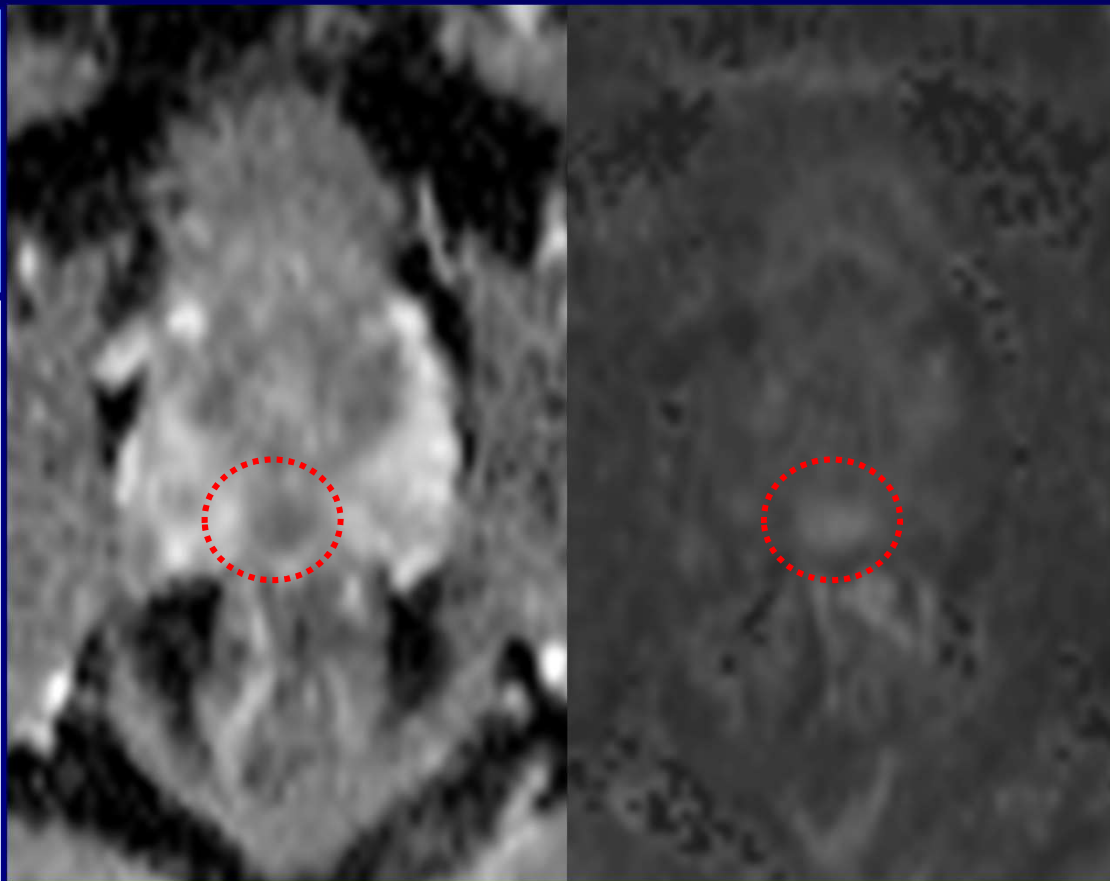
Linear/wedge shaped hypointense on ADC and/or hyperintense on high b-value DWI



# DWI in PERIPHERAL ZONE

## PIRADS 3

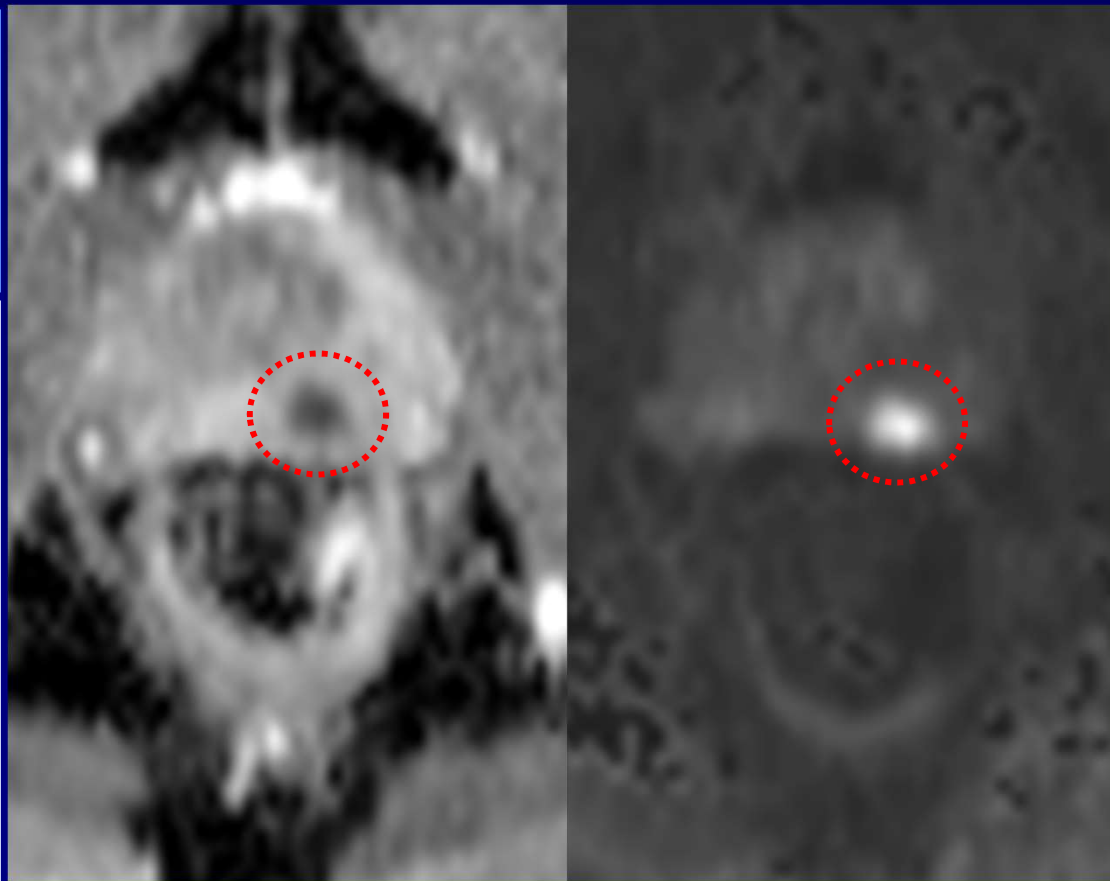
Focal hypointense on ADC and hyperintense on high b-value DWI; if marked, then not on both



# DWI in PERIPHERAL ZONE

## PIRADS 4

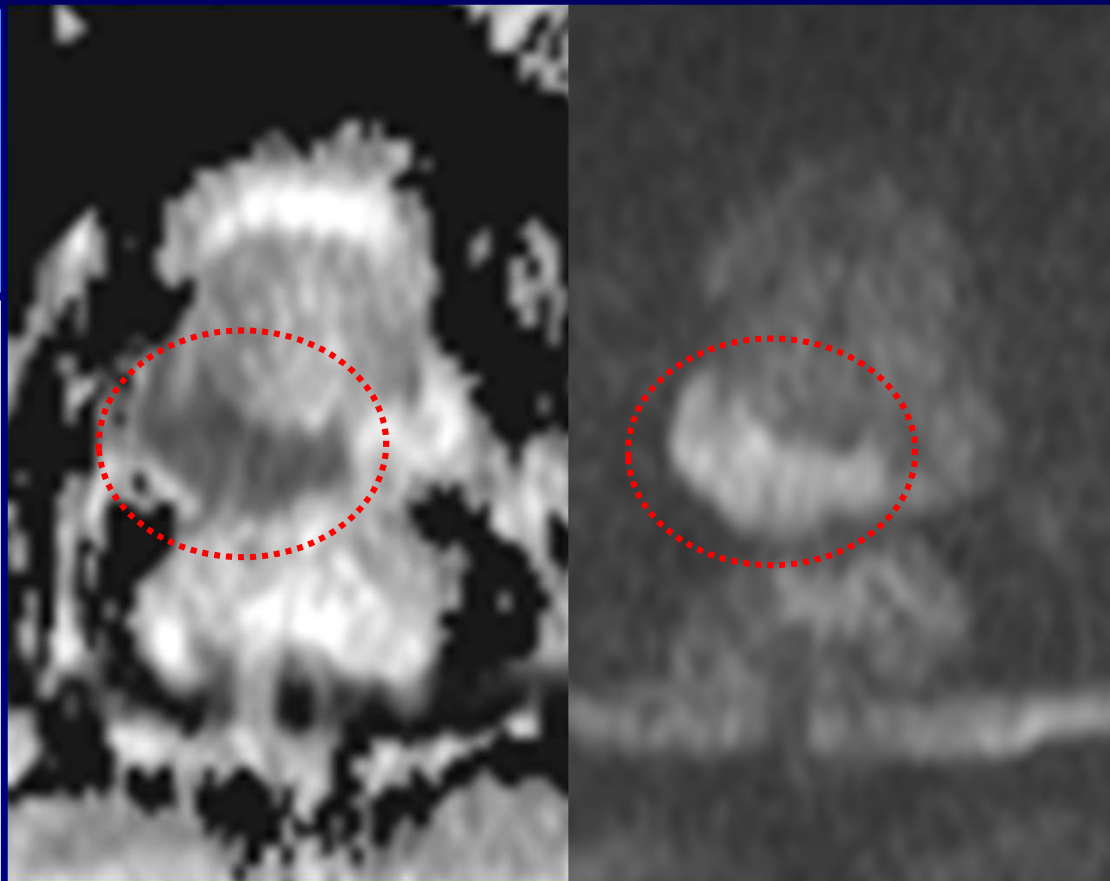
Focal markedly hypointense on ADC and markedly hyperintense on high b-value DWI; < 15mm



# DWI in PERIPHERAL ZONE

## PIRADS 5

Same as 4, but  
 $\geq 15$  mm or  
definite  
extraprostatic  
extension/  
invasive behavior



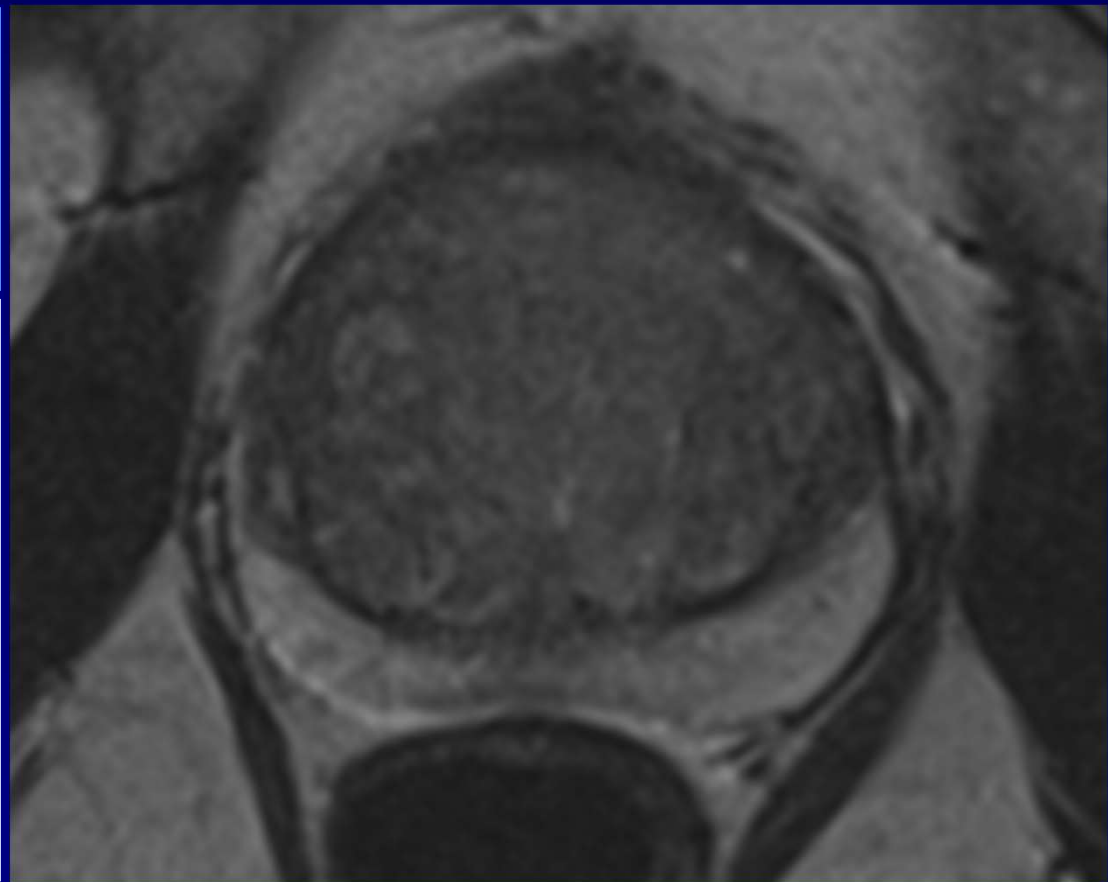
# Multiparametric MRI

- PIRADSv2
  - Assessment and reporting
    - PZ: dominance of DWI
    - TZ: dominance of T2

# T2W in TRANSITION ZONE

## PIRADS 1

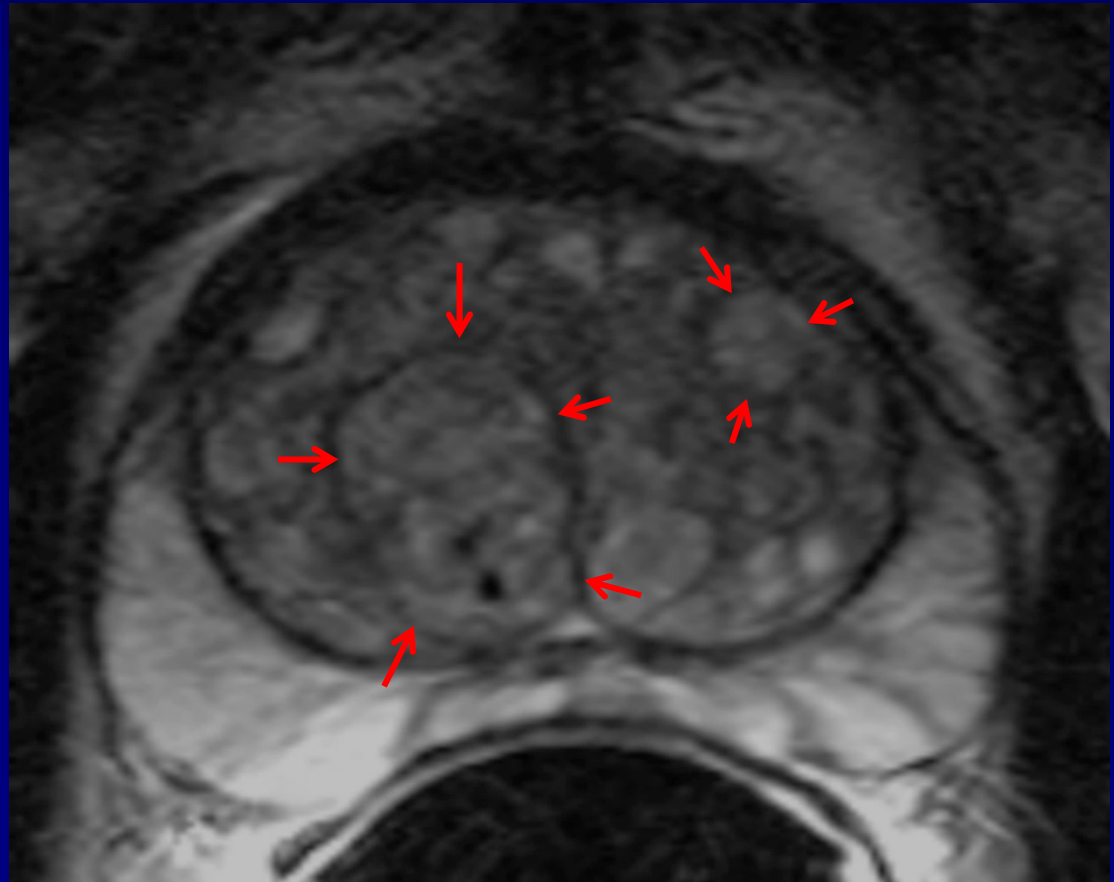
Homogeneous  
intermediate  
signal intensity or  
round, completely  
encapsulated  
nodule



# T2W in TRANSITION ZONE

## PIRADS 1

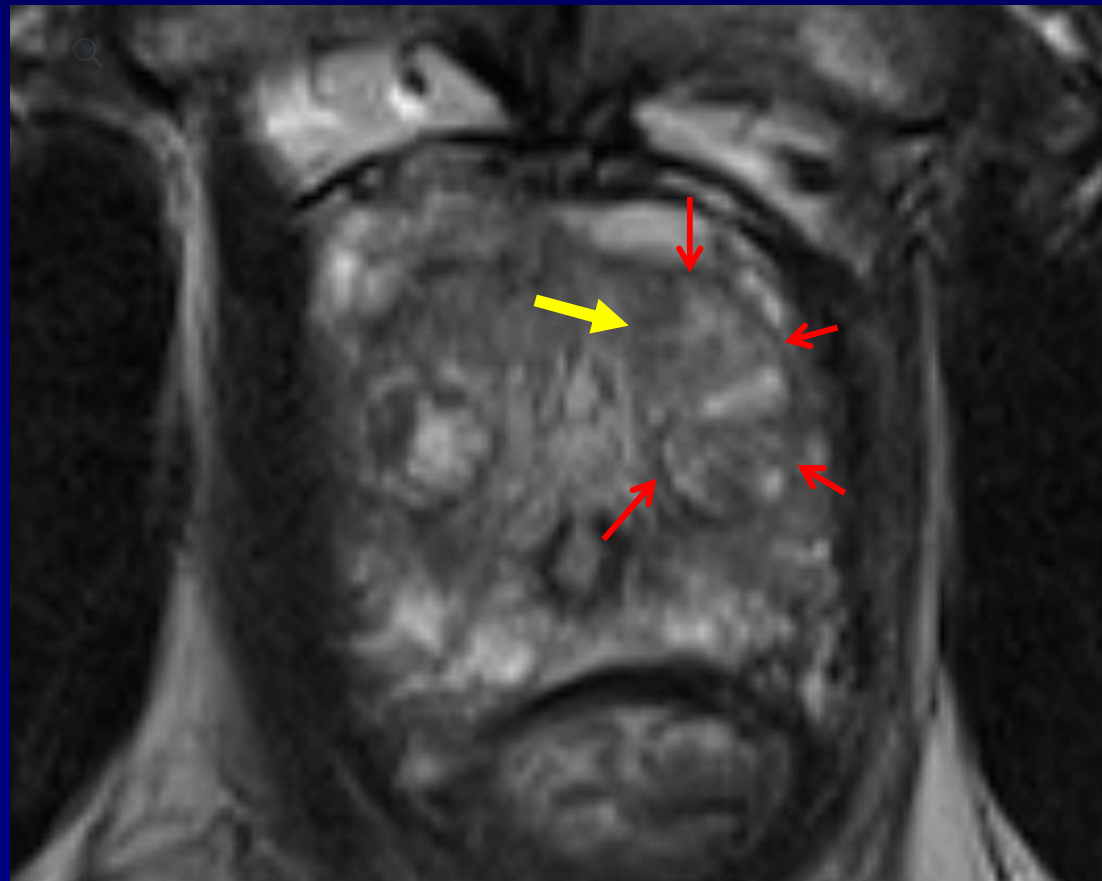
Homogeneous  
intermediate  
signal intensity or  
round, completely  
encapsulated  
nodule



# T2W in TRANSITION ZONE

## PIRADS 2

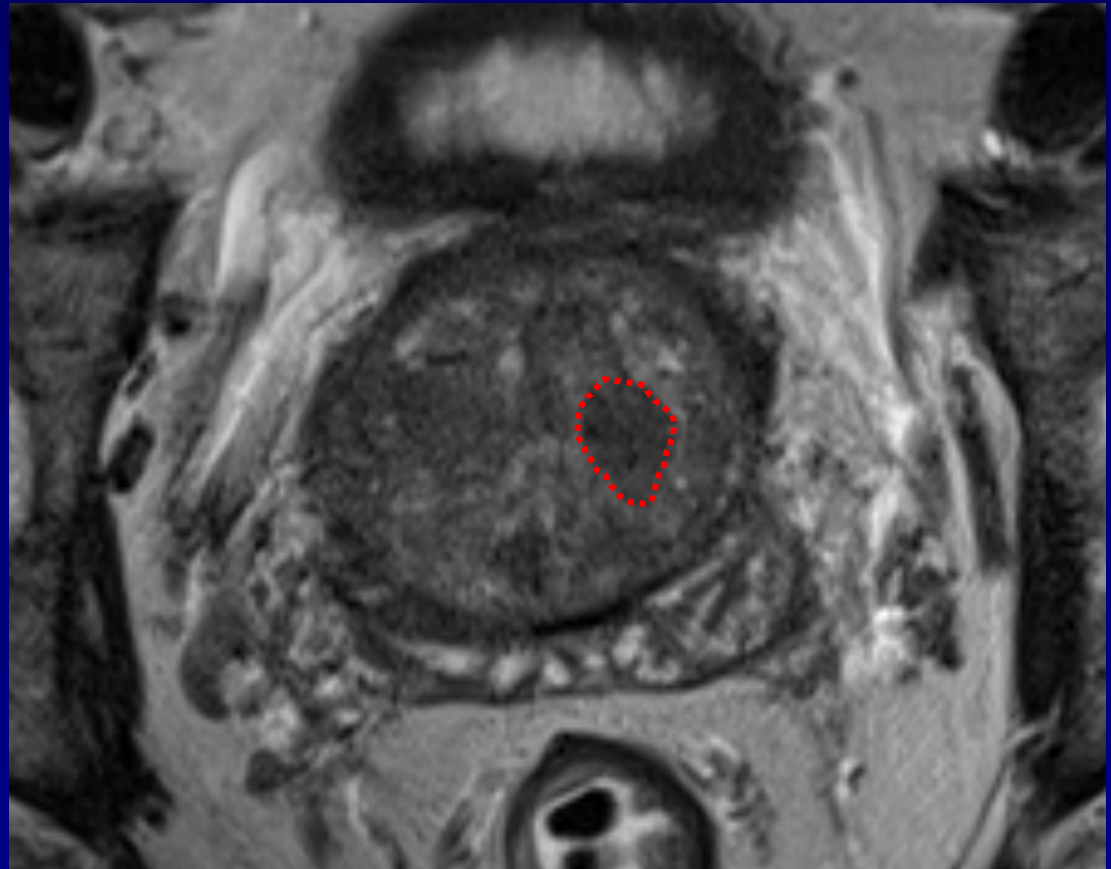
Mostly  
encapsulated  
nodule



# T2W in TRANSITION ZONE

## PIRADS 2

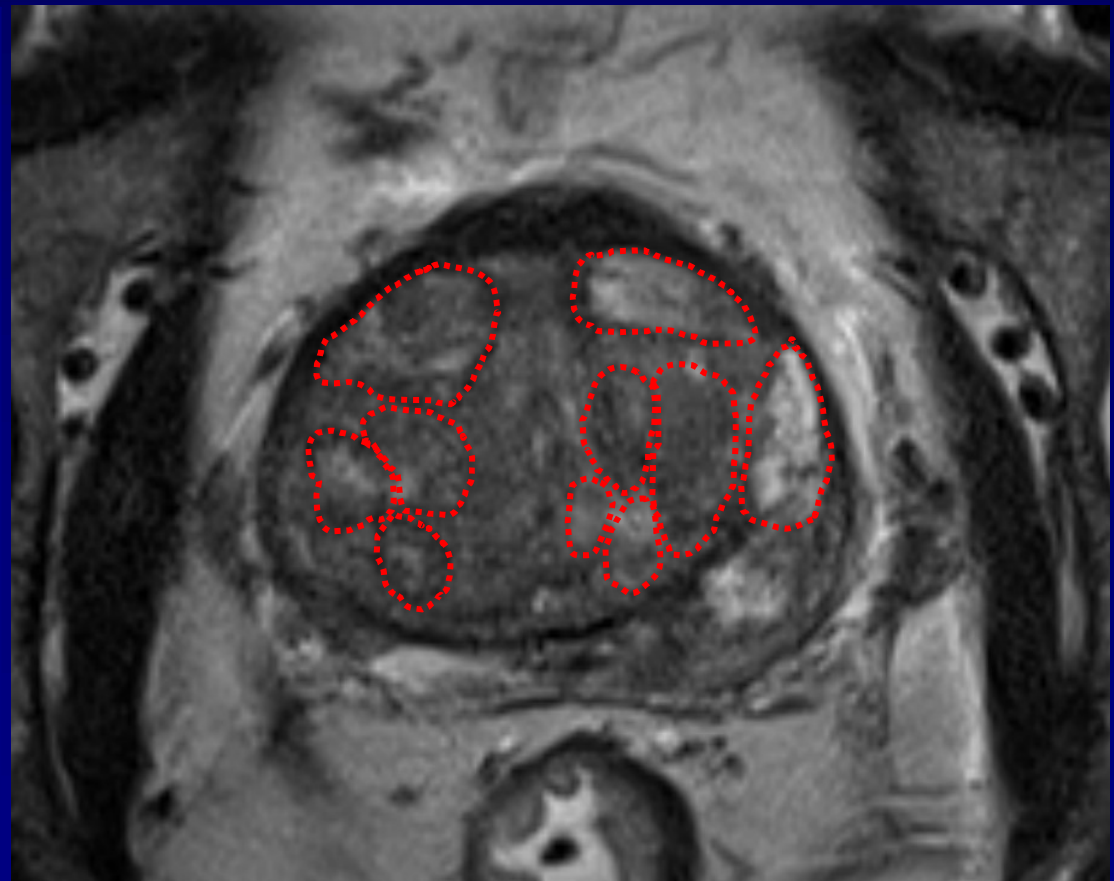
Homogeneous  
circumscribed  
nodule without  
encapsulation  
("atypical nodule")



# T2W in TRANSITION ZONE

## PIRADS 2

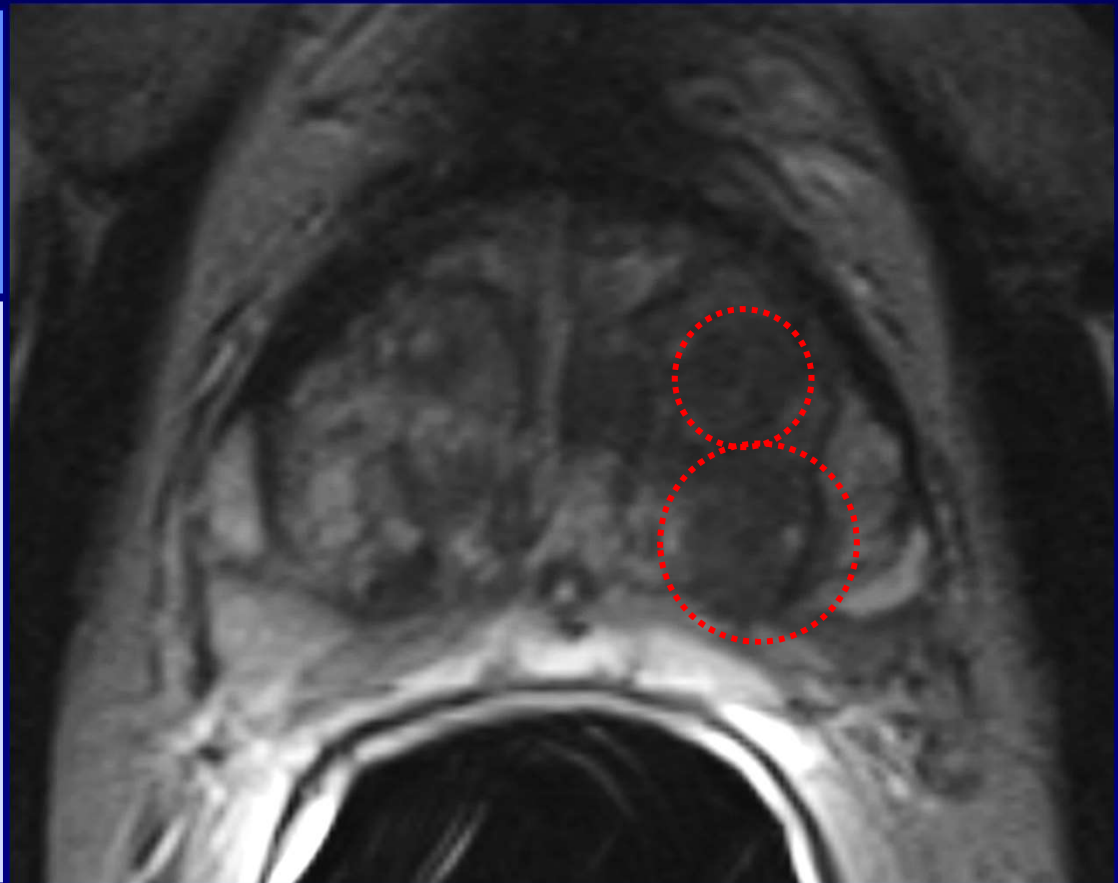
Homogeneous  
mildly  
hypointense area  
**BETWEEN**  
nodules



# T2W in TRANSITION ZONE

## PIRADS 3

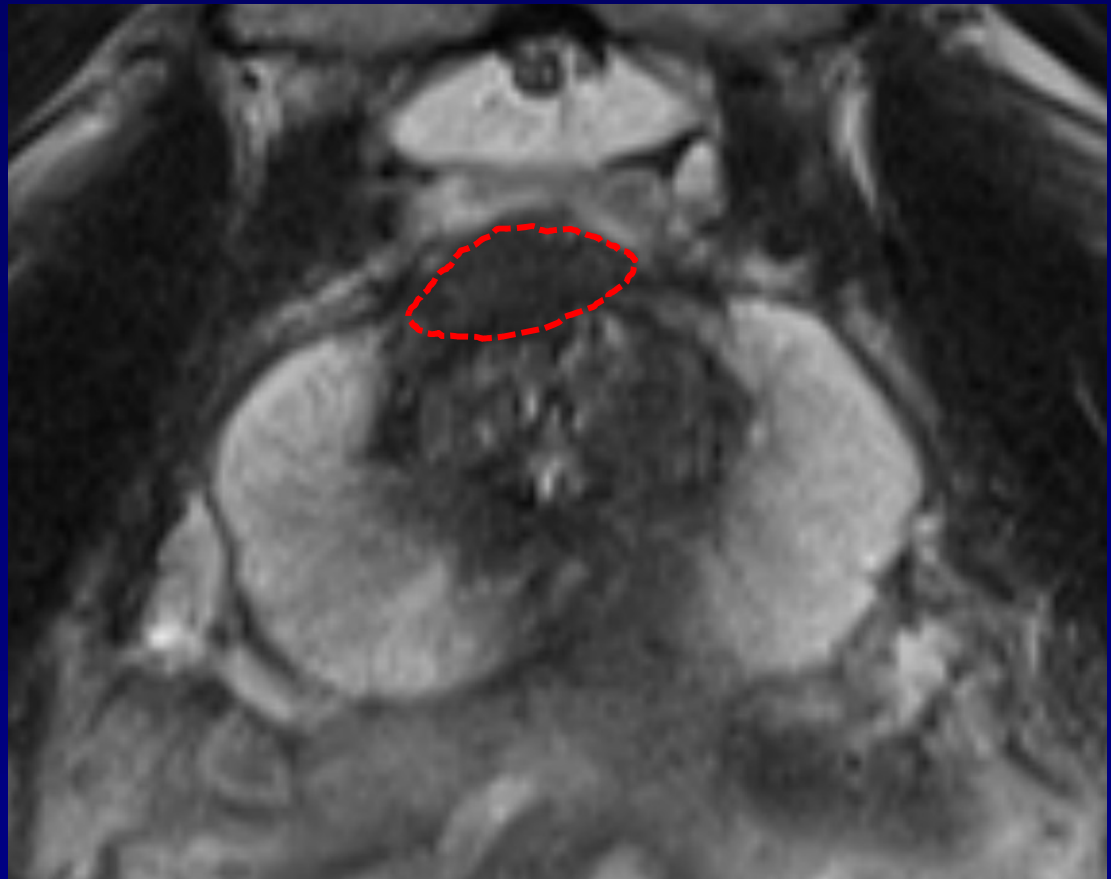Heterogeneous  
signal intensity  
with obscured  
margins  
Includes others  
that do not qualify  
as 2, 4 or 5



# T2W in TRANSITION ZONE

## PIRADS 4

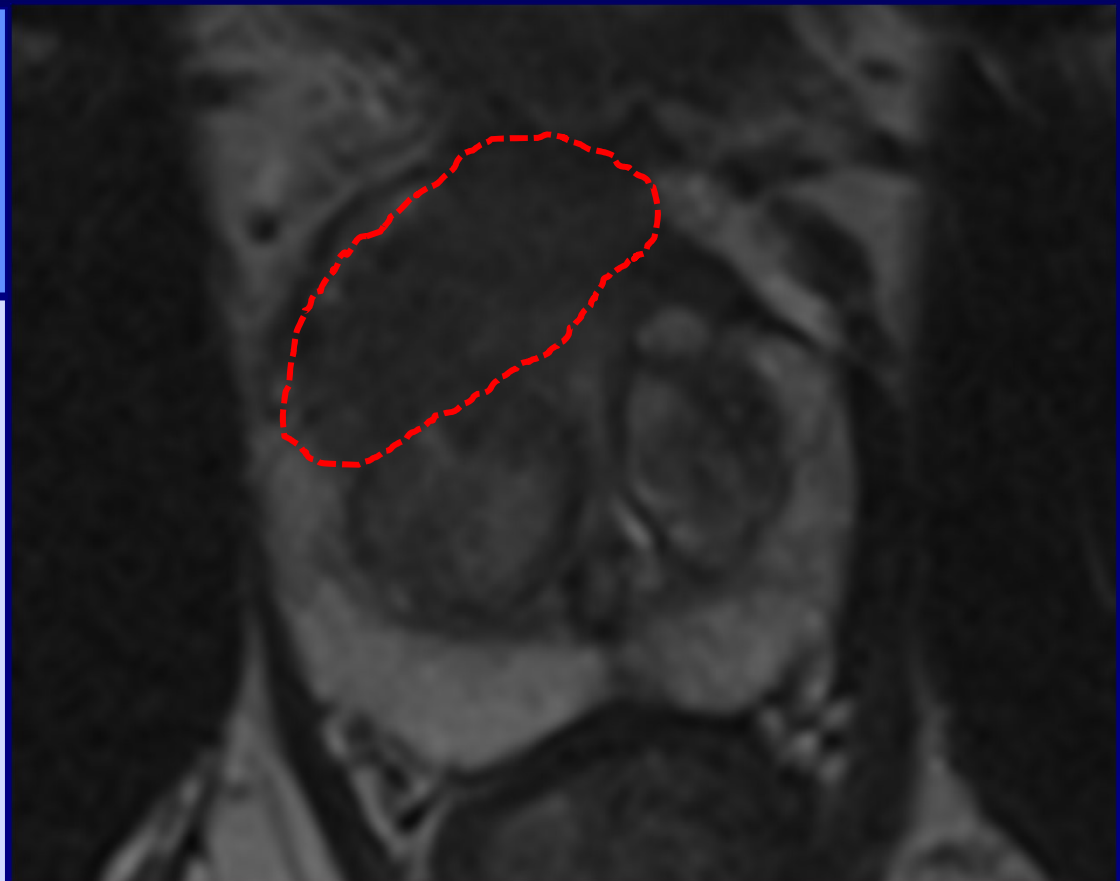
Lenticular or non-circumscribed, homogeneous, moderately hypointense, and < 15mm



# T2W in TRANSITION ZONE

## PIRADS 5

Same as 4, but  
 $\geq 15$  mm or  
definite  
extraprostatic  
extension/  
invasive behavior



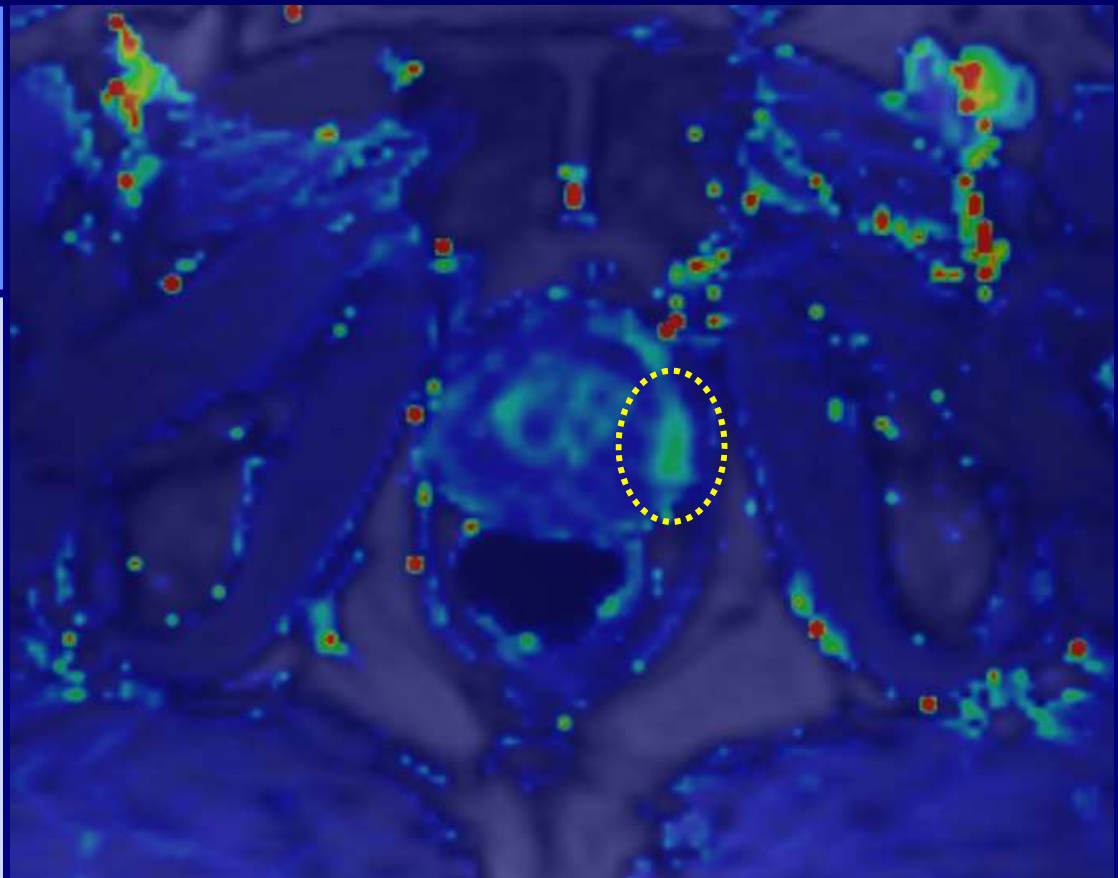
# Multiparametric MRI

- PIRADSv2
  - Assessment and reporting
    - PZ: dominance of DWI
    - TZ: dominance of T2
    - DCE: problem solving in peripheral zone

# PI-RADS

**DCE (+)**

**Focal** and  $\leq$  enhancement of **adjacent normal tissue** and corresponding to a finding on DWI (and/or T2)



# PI-RADS

PIRADS	mpMRI probability of clinically significant disease
1	Clinically significant disease is <b>very unlikely</b>

# PI-RADS

PIRADS	mpMRI probability of clinically significant disease
1	Clinically significant disease is <b>very unlikely</b>
5	Clinically significant disease is <b>very likely</b>

# PI-RADS

PIRADS	mpMRI probability of clinically significant disease
1	Clinically significant disease is <b>very unlikely</b>
2	Clinically significant disease is <b>unlikely</b>
3	Clinically significant disease is <b>equivocal</b>
4	Clinically significant disease is <b>likely</b>
5	Clinically significant disease is <b>very likely</b>

# PI-RADS

**PZ**

**PI-RADS**

**DWI**

**1**

**1**

**2**

**2**

**3**

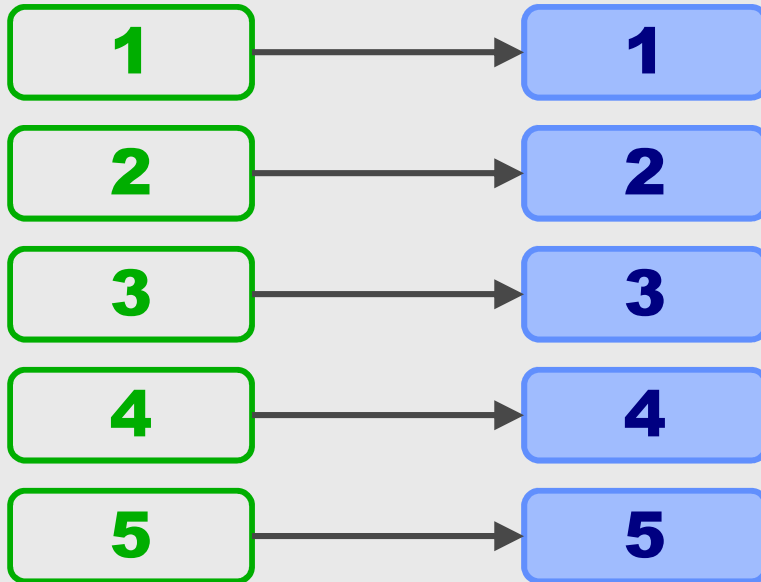
**3**

**4**

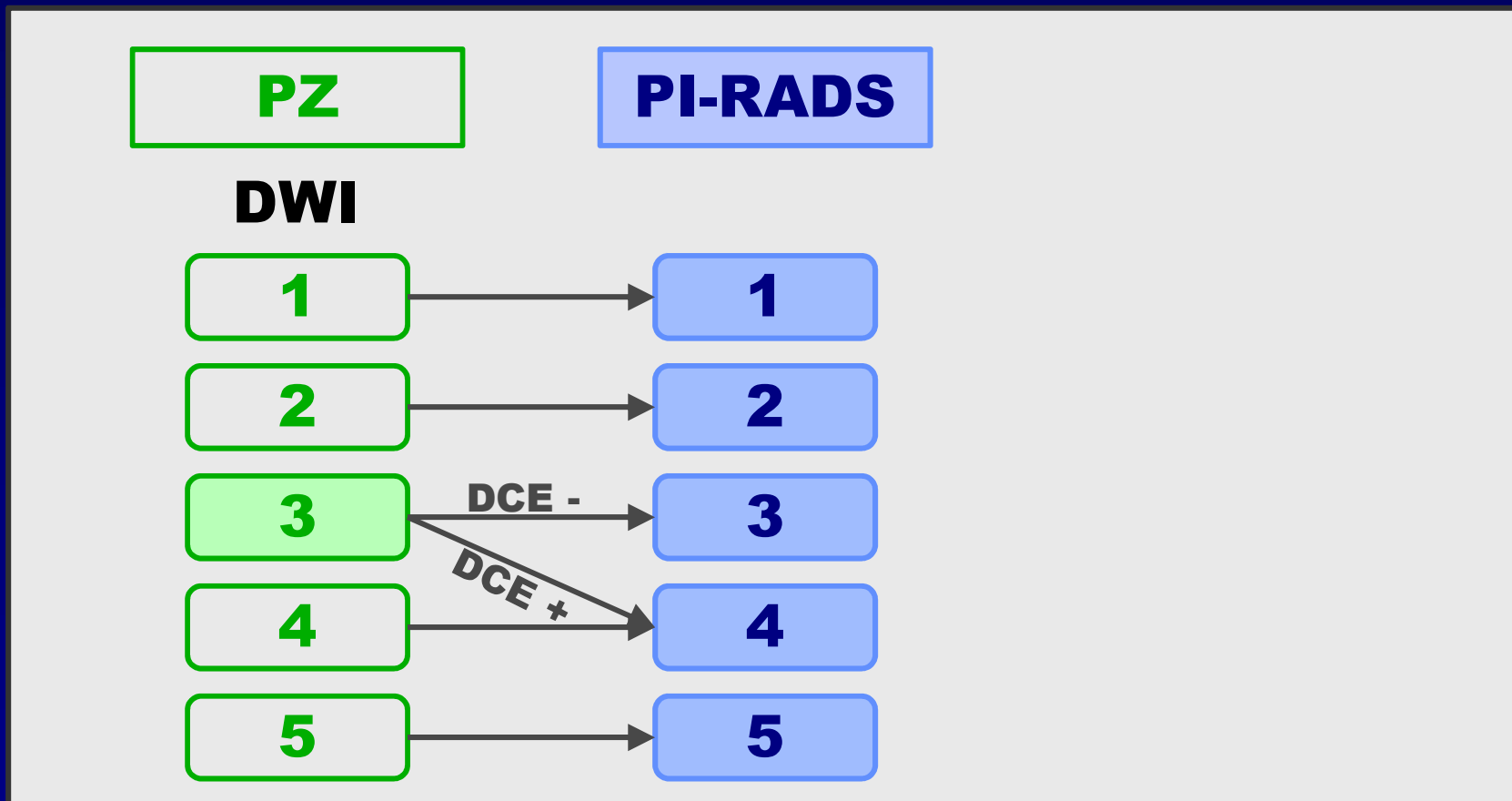
**4**

**5**

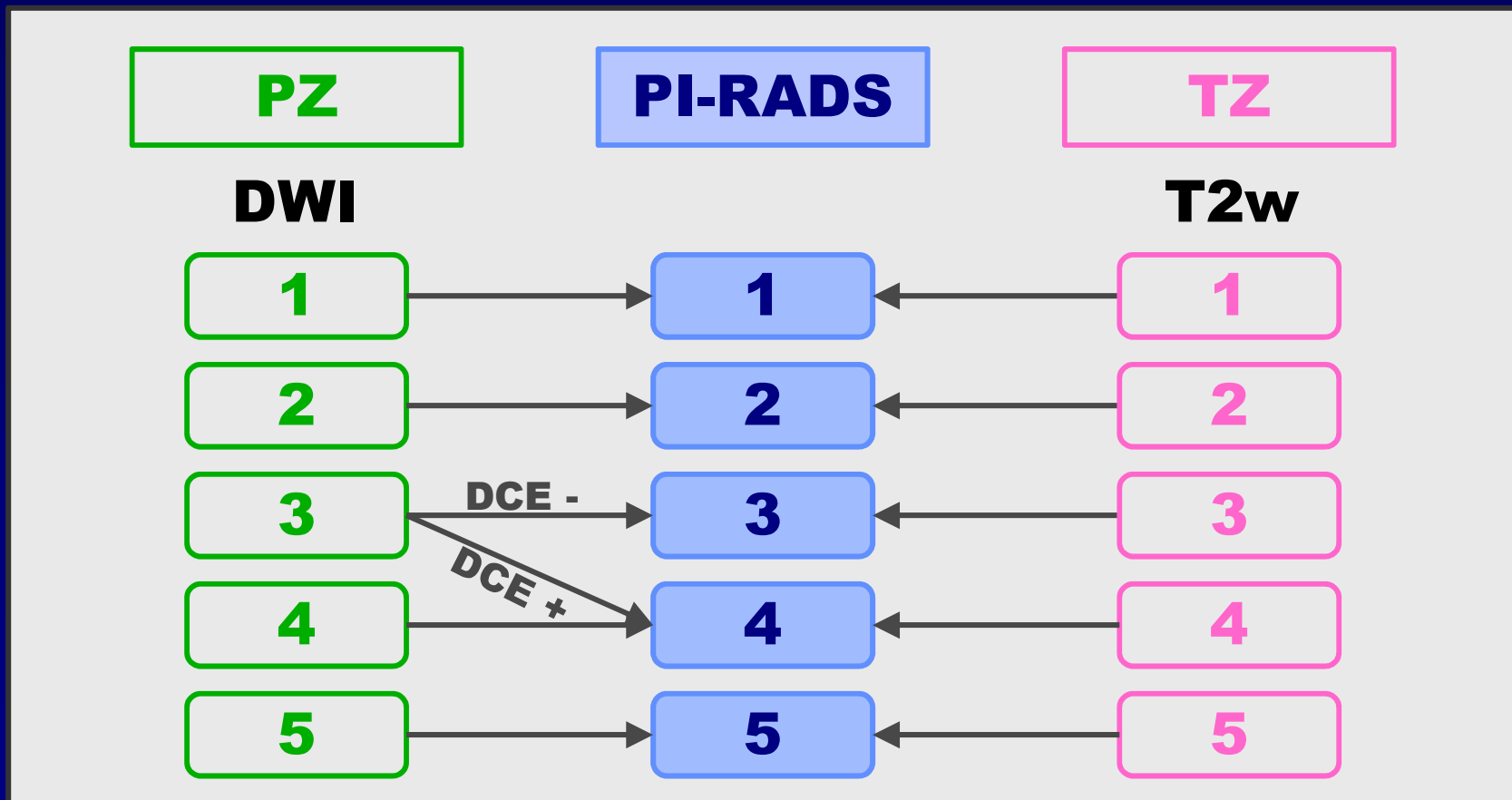
**5**



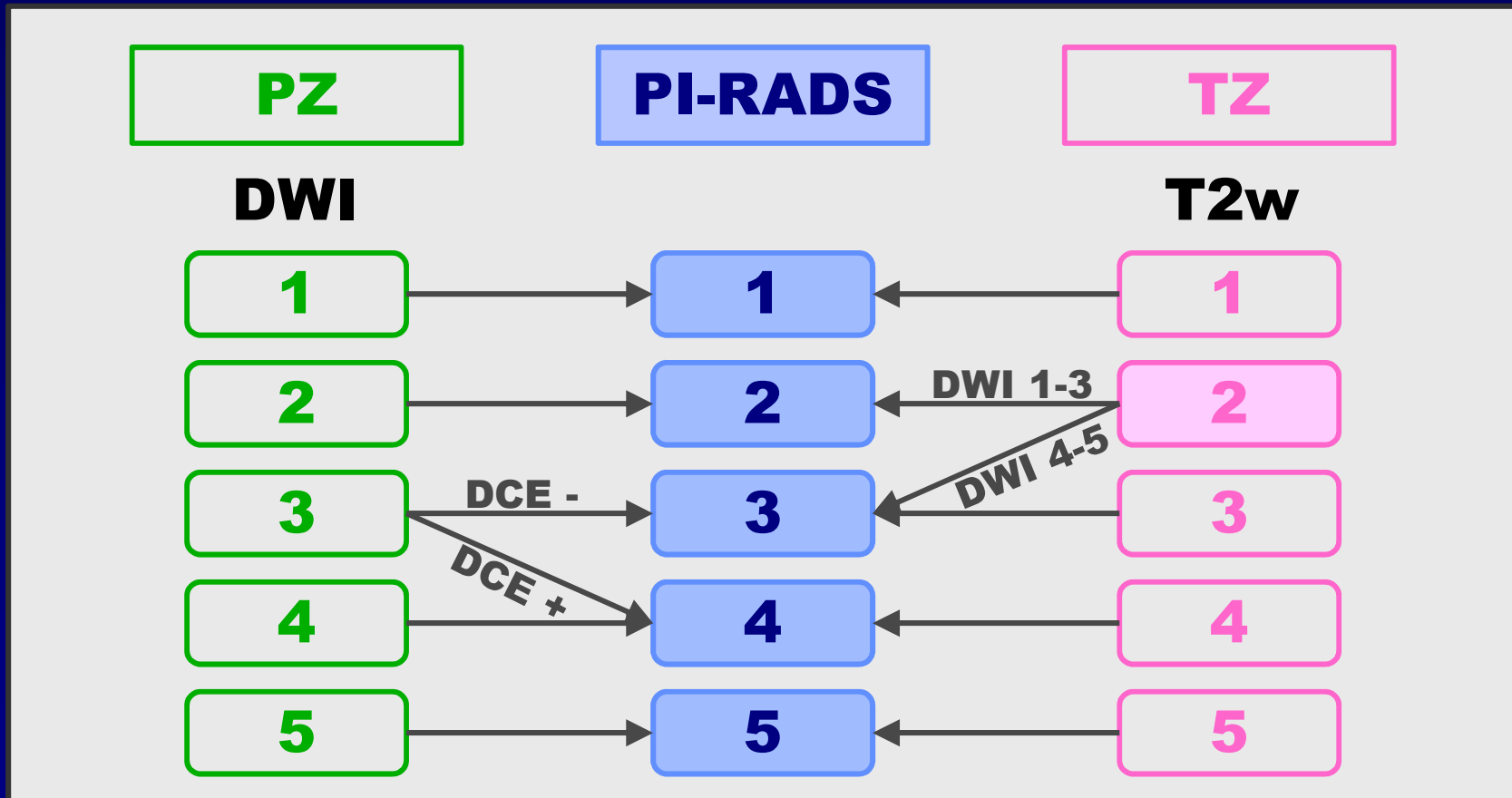
# PI-RADS



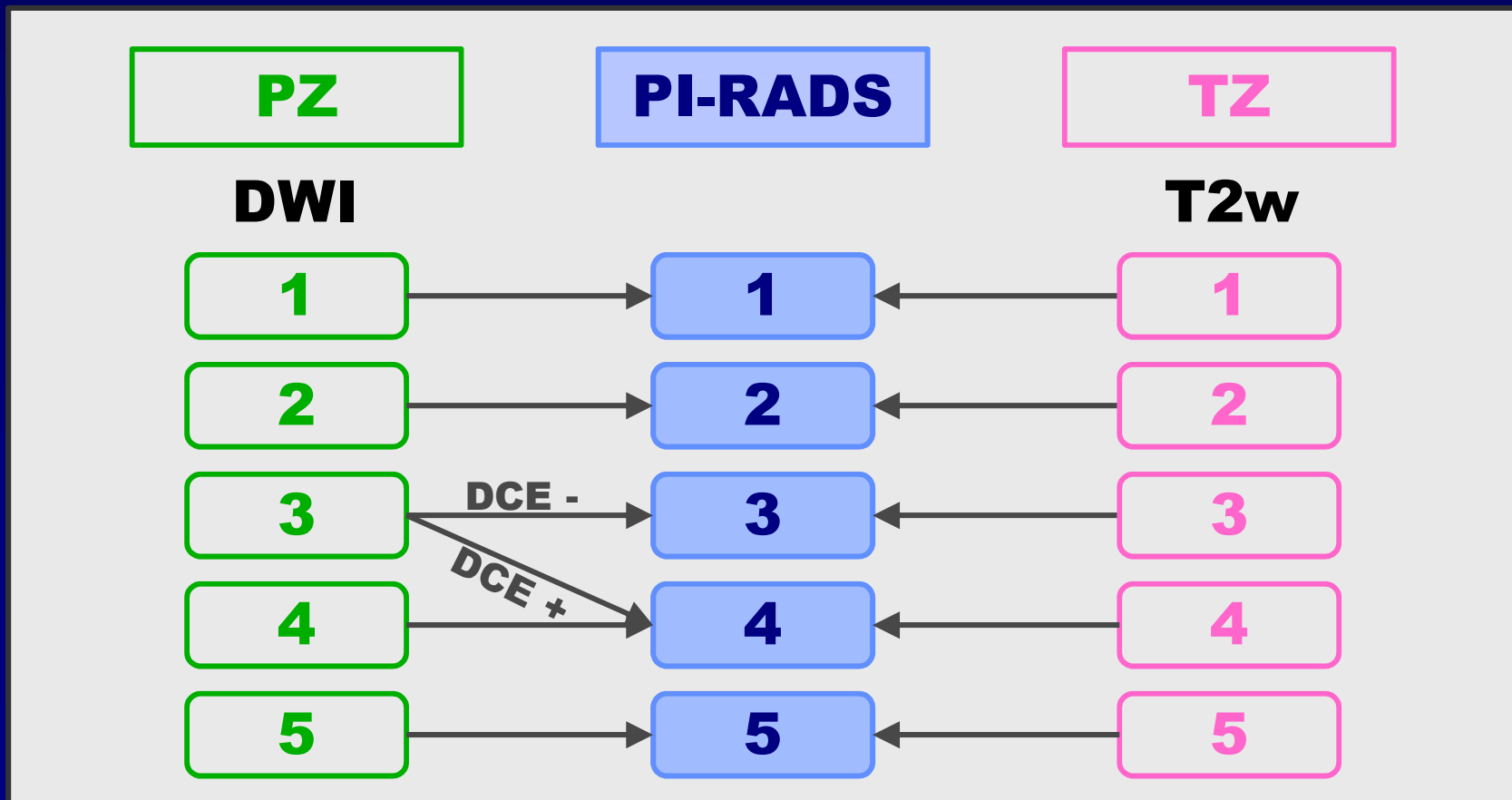
# PI-RADS



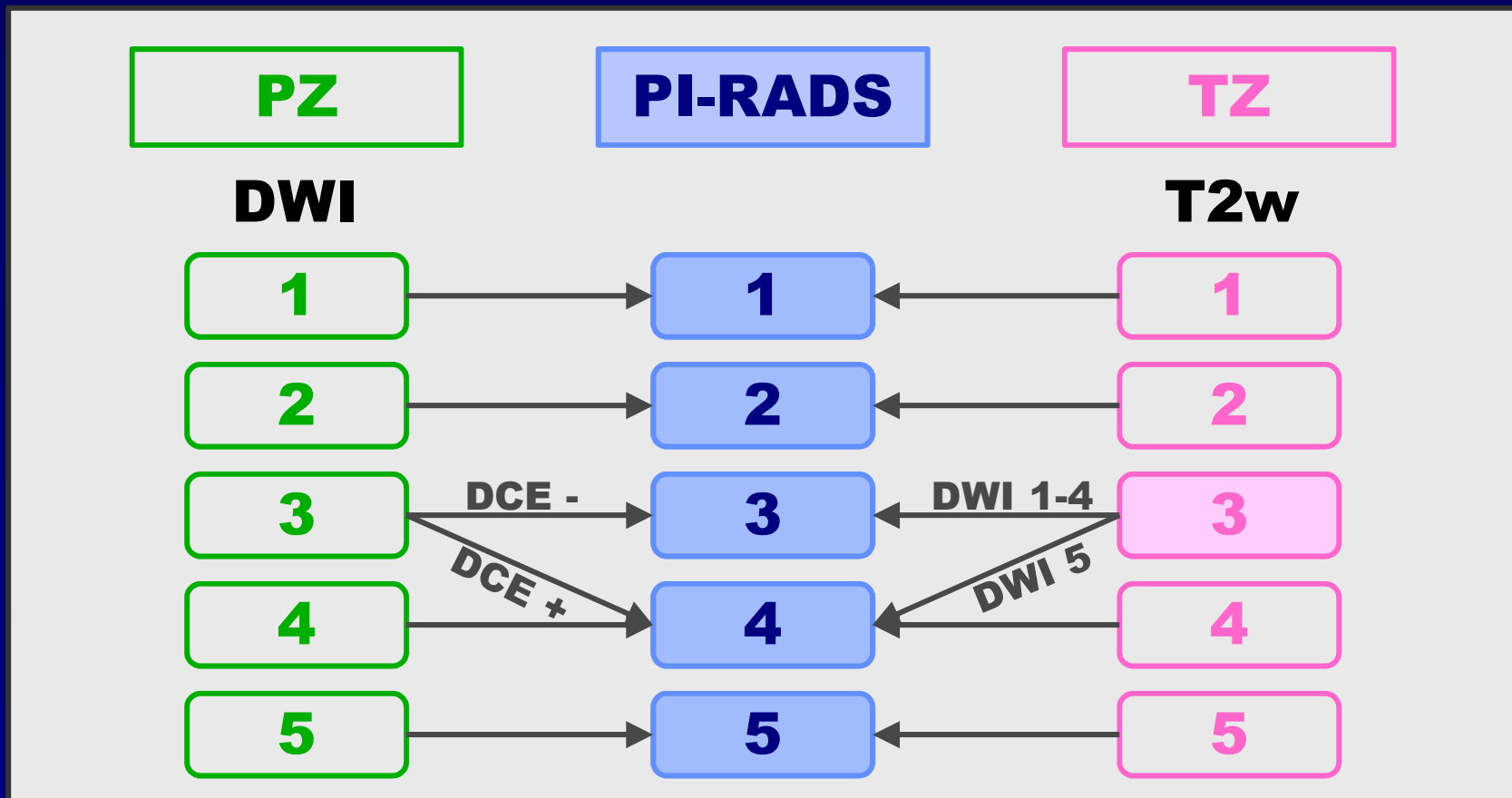
# PI-RADS



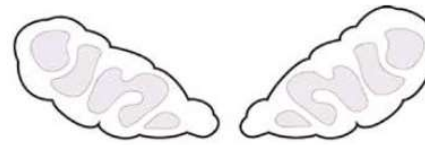
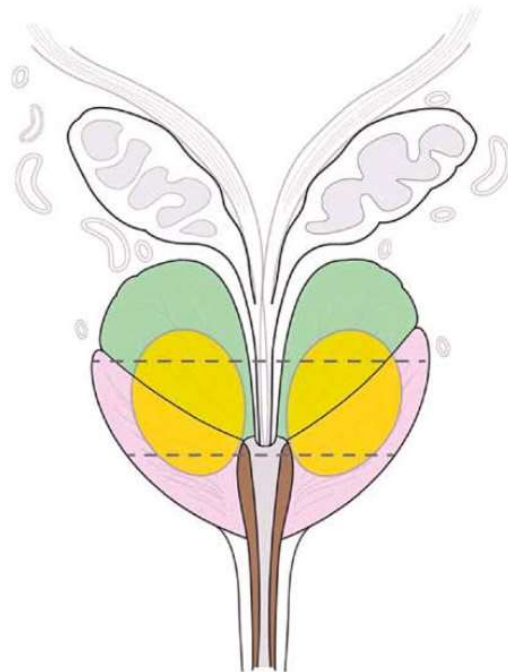
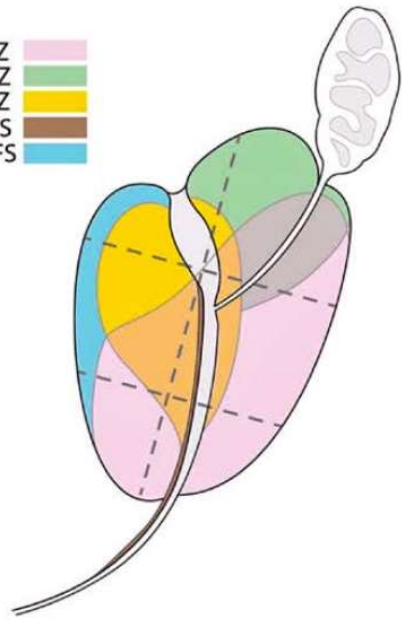
# PI-RADS



# PI-RADS

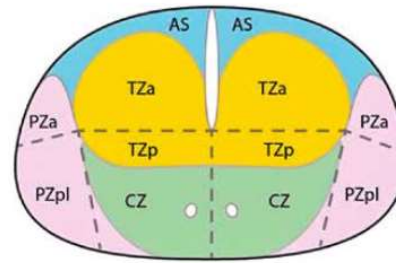


PZ  
 CZ  
 TZ  
 US  
 AFS

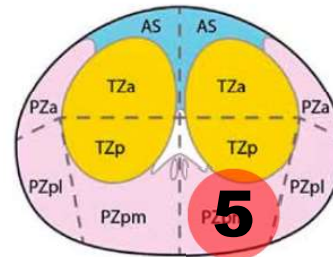


Seminal Vesicles

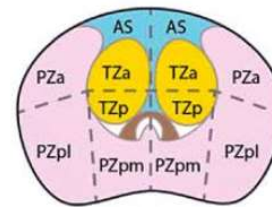
R L



Base



Mid




Apex



Urethra

# Validation of mpMRI using PI-RADS?

available at [www.sciencedirect.com](http://www.sciencedirect.com)  
journal homepage: [www.europeanurology.com](http://www.europeanurology.com)



Platinum Priority – Review – Prostate Cancer  
*Editorial by XXX on pp. x-y of this issue*

# Diagnostic Performance of Prostate Imaging Reporting and Data System Version 2 for Detection of Prostate Cancer: A Systematic Review and Diagnostic Meta-analysis

Sungmin Woo<sup>a,†</sup>, Chong Hyun Suh<sup>b,c,†</sup>, Sang Youn Kim<sup>a,\*</sup>, Jeong Yeon Cho<sup>a,d</sup>, Seung Hyup Kim<sup>a,d</sup>

<sup>a</sup>Department of Radiology, Seoul National University College of Medicine, Seoul, Korea; <sup>b</sup>Department of Radiology and Research Institute of Radiology, University of Ulsan College of Medicine, Asan Medical Center, Seoul, Republic of Korea; <sup>c</sup>Department of Radiology, Namwon Medical Center, Jeollabuk-do, Republic of Korea; <sup>d</sup>Institute of Radiation Medicine and Kidney Research Institute, Seoul National University Medical Research Center, Seoul, Korea

## Article info

### Article history:

## Abstract

**Context:** In 2015, the updated Prostate Imaging Reporting and Data System version 2

# Validation of PI-RADS

- Meta-analysis of 21 single-institution studies, including 3857 patients
  - sensitivity range : 73% - 100%
  - specificity range : 7% - 100%

# Validation of PI-RADS

- Meta-analysis of 21 single-institution studies, including 3857 patients
  - sensitivity range : 73% - 100%, pooled 89%
  - specificity range : 7% - 100%, pooled 73%

# Validation of PI-RADS

- What is the impact of:
  - technical parameters (magnet strength, coil use, ...)
  - outcome variables (all cancers versus clinically significant cancers only)
  - clinical scenarios (biopsy naive, prior negative biopsy, known cancer)

# Impact of technical parameters

# Impact of technique

- Do we need a 3T with ERC?
  - no difference between 1.5T and 3.0T
  - no difference between ERC or no ERC
  - good results also possible on state-of-the-art (strong gradients, multiple channels) 1.5T system without ERC

# Impact of tumor aggressiveness

# Prospective Evaluation of PI-RADS™ Version 2 Using the International Society of Urological Pathology Prostate Cancer Grade Group System



Sherif Mehralivand,\* Sandra Bednarova,\* Joanna. H. Shih, Francesca V. Mertan, Sonia Gaur, Maria J. Merino, Bradford J. Wood,† Peter A. Pinto,‡ Peter L. Choyke and Baris Turkbey§

*From the Department of Urology and Pediatric Urology, University Medical Center (SM), Mainz, Germany, Urologic Oncology Branch (SM, PAP), Molecular Imaging Program (SM, SB, FVM, SG, PLC, BT), Center for Interventional Oncology (SB, BJW), Laboratory of Pathology, National Cancer Institute (MJM) and Radiology and Imaging Sciences, Clinical Center (SB, BJW), National Institutes of Health, Bethesda and Biometric Research Program, Division of Cancer Treatment and Diagnosis, National Cancer Institute, National Institutes of Health (JHS), Rockville, Maryland, and Institute of Diagnostic Radiology, Department of Medical and Biological Sciences, University of Udine (SB), Udine, Italy*

**Purpose:** The PI-RADS™ (Prostate Imaging Reporting and Data System), version 2 scoring system, introduced in 2015, is based on expert consensus. In the same time frame ISUP (International Society of Urological Pathology) introduced a new pathological scoring system for prostate cancer. Our goal was to prospectively evaluate the cancer detection rates for each PI-RADS, version 2 category and compare them to ISUP group scores in patients undergoing systematic biopsy and magnetic resonance imaging-transrectal ultrasound fusion guided biopsy.

**Materials and Methods:** A total of 339 treatment naïve patients prospectively underwent multiparametric magnetic resonance imaging evaluated with PI-RADS, version 2 with subsequent systematic and fusion guided biopsy from May 2015 to May 2016. ISUP scores were applied to pathological specimens. An

## Abbreviations and Acronyms

CDR = cancer detection rate

CS = clinically significant

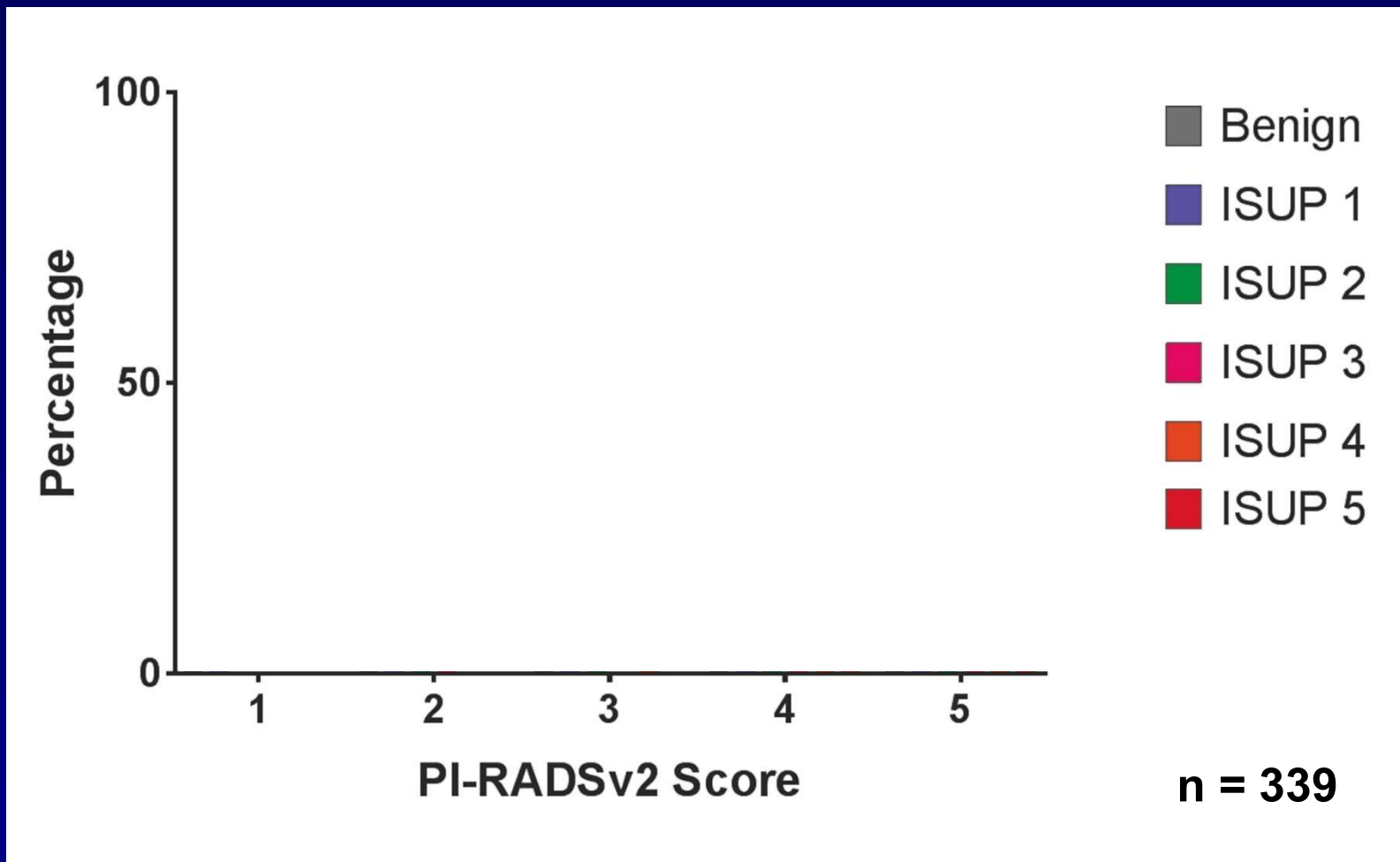
DCE = dynamic contrast enhanced

DWI = diffusion-weighted imaging

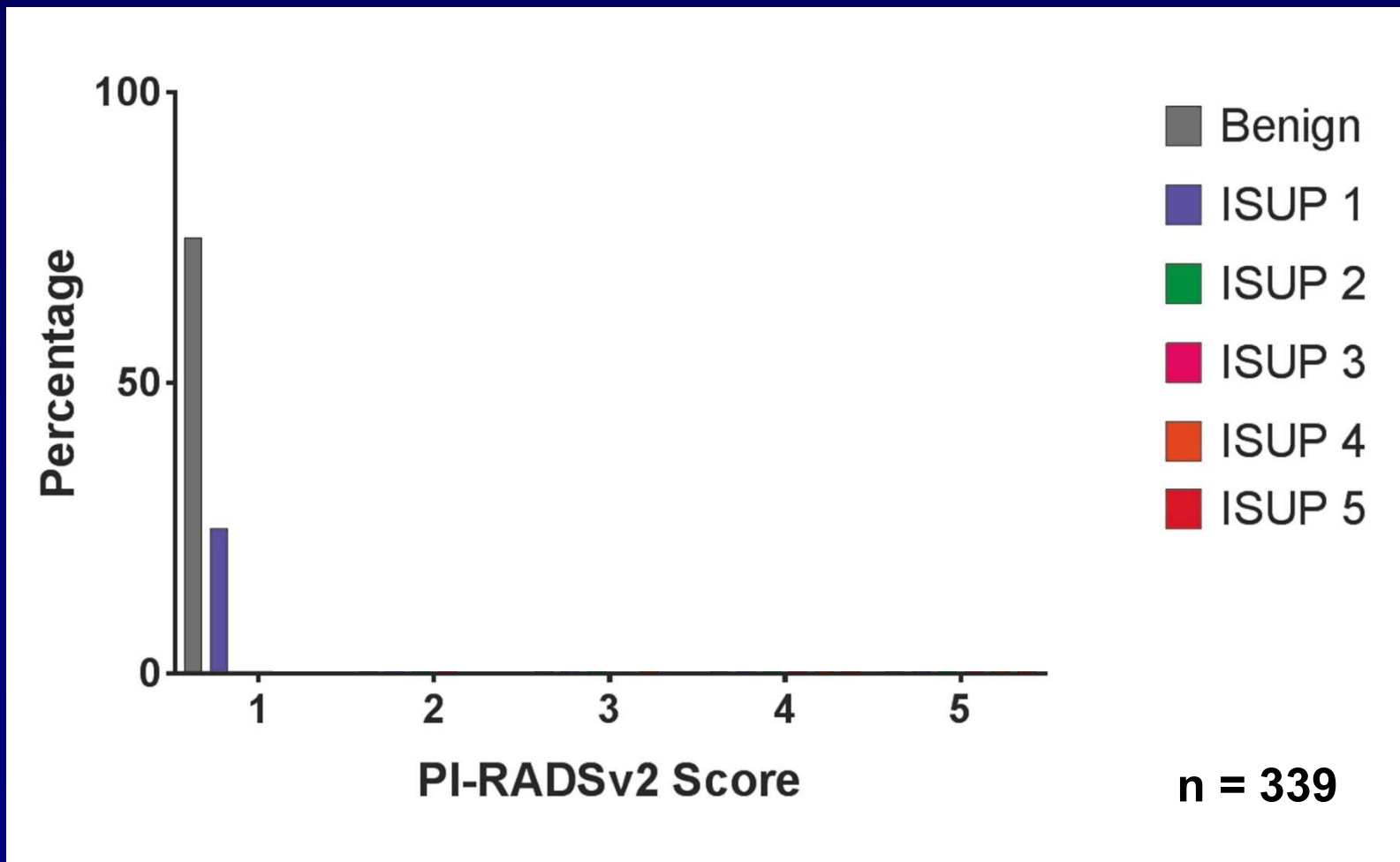
ISUP = International Society of Urological Pathology

mpMRI = multiparametric MRI

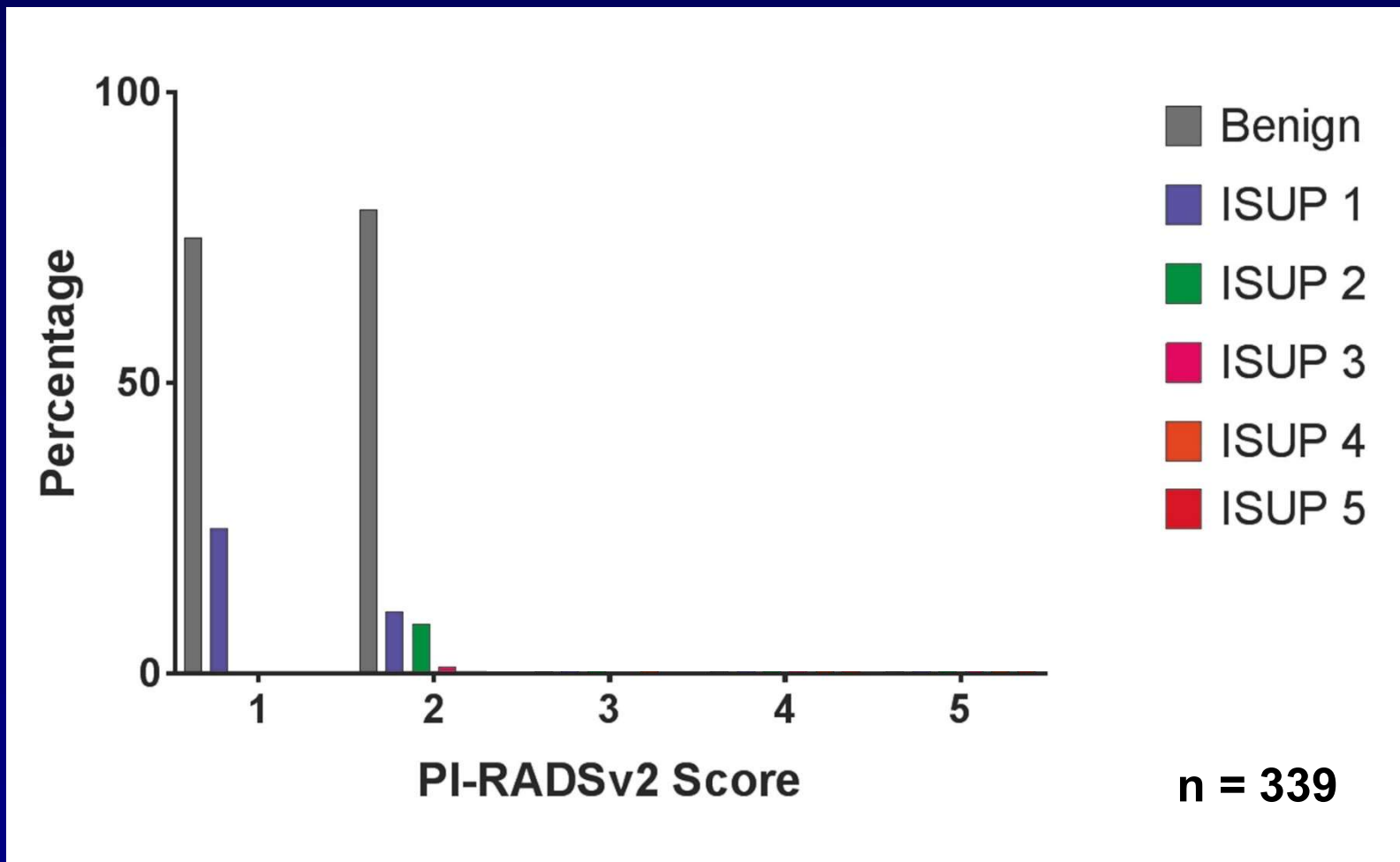
# mpMRI vs. cancer aggressiveness



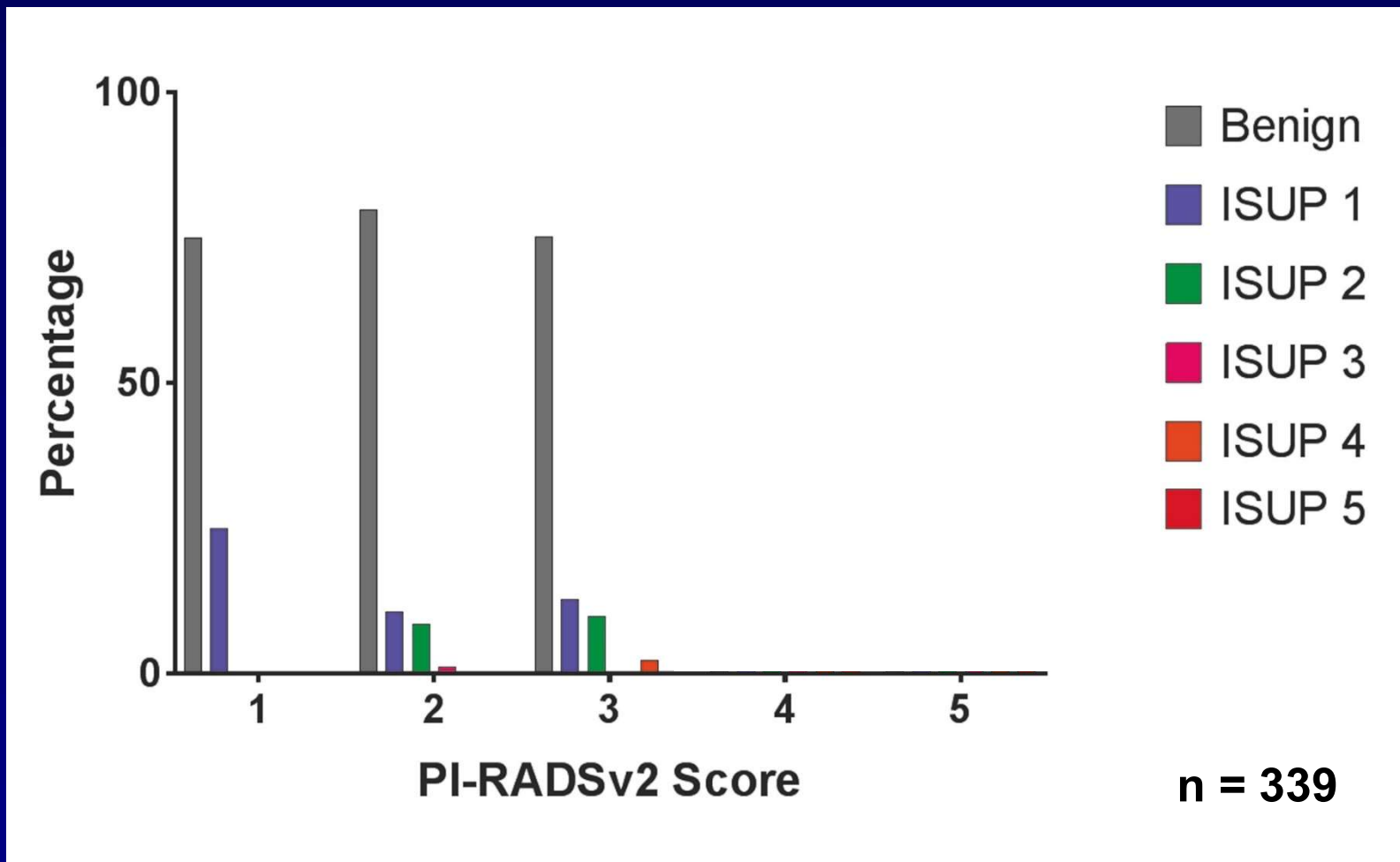
# mpMRI vs. cancer aggressiveness



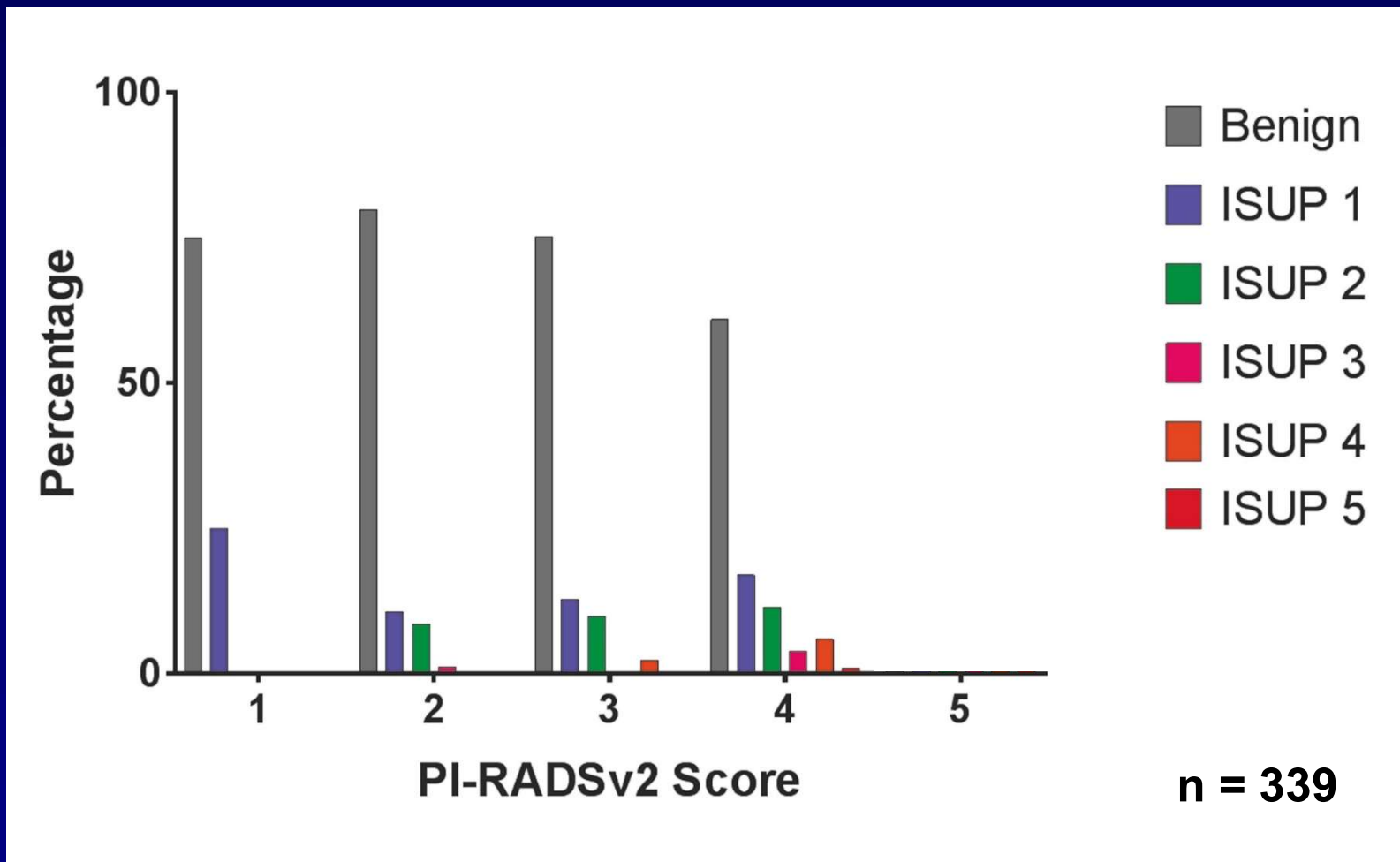
# mpMRI vs. cancer aggressiveness



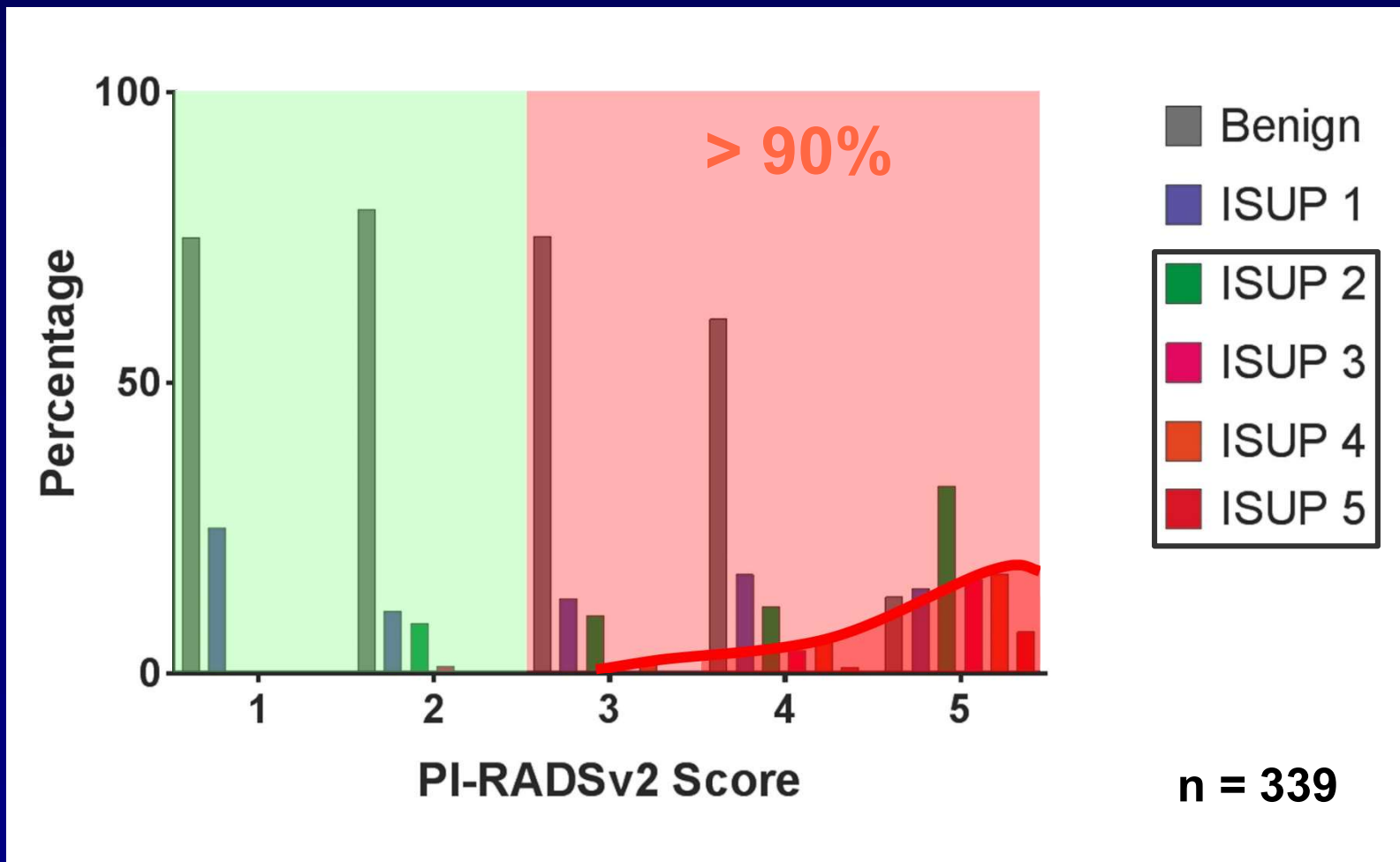
# mpMRI vs. cancer aggressiveness



# mpMRI vs. cancer aggressiveness



# mpMRI vs. cancer aggressiveness



# Rationale of mpMRI

- If mpMRI is negative (PI-RADS 1-2):  
do not biopsy (high NPV for excluding clinically significant cancer)
- If mpMRI is positive (PI-RADS 3-5):  
target biopsy needle towards mpMRI visible lesion



## Review – Prostate Cancer

# What Is the Negative Predictive Value of Multiparametric Magnetic Resonance Imaging in Excluding Prostate Cancer at Biopsy? A Systematic Review and Meta-analysis from the European Association of Urology Prostate Cancer Guidelines Panel

Paul C. Moldovan<sup>a,†</sup>, Thomas Van den Broeck<sup>b,c,†</sup>, Richard Sylvester<sup>d</sup>, Lorenzo Marconi<sup>e</sup>, Joaquim Bellmunt<sup>f,g</sup>, Roderick C.N. van den Bergh<sup>h</sup>, Michel Bolla<sup>i</sup>, Erik Briers<sup>j</sup>, Marcus G. Cumberbatch<sup>k</sup>, Nicola Fossati<sup>l</sup>, Tobias Gross<sup>m</sup>, Ann M. Henry<sup>n</sup>, Steven Joniau<sup>b,c</sup>, Theo H. van der Kwast<sup>o</sup>, Vsevolod B. Matveev<sup>p</sup>, Henk G. van der Poel<sup>h</sup>, Maria De Santis<sup>q</sup>, Ivo G. Schoots<sup>r,s</sup>, Thomas Wiegel<sup>t</sup>, Cathy Yuhong Yuan<sup>u</sup>, Philip Cornford<sup>v</sup>, Nicolas Mottet<sup>w</sup>, Thomas B. Lam<sup>x,y</sup>, Olivier Rouvière<sup>a,z,\*</sup>

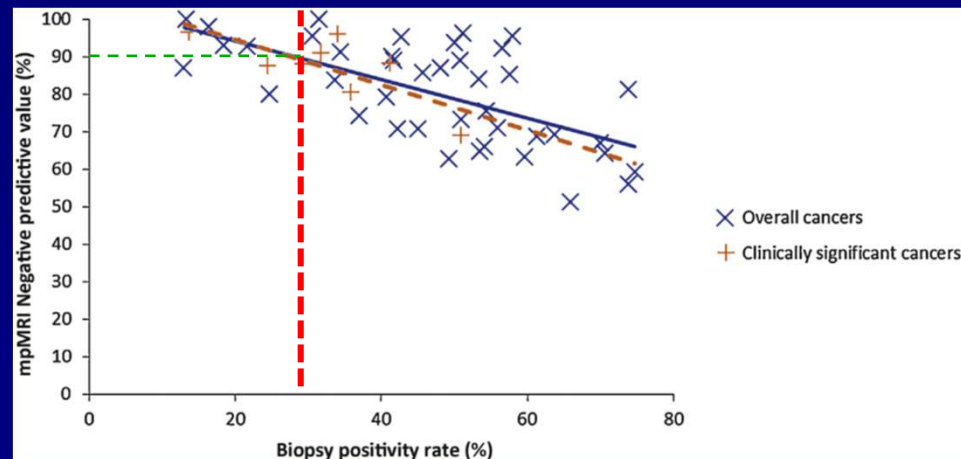
<sup>a</sup>Hospices Civils de Lyon, Department of Urinary and Vascular Radiology, Hôpital Edouard Herriot, Lyon, France; <sup>b</sup>Department of Urology, University Hospitals Leuven, Leuven, Belgium; <sup>c</sup>Laboratory of Molecular Endocrinology, KU Leuven, Leuven, Belgium; <sup>d</sup>European Association of Urology Guidelines Office, Brussels, Belgium; <sup>e</sup>Department of Urology, Coimbra University Hospital, Coimbra, Portugal; <sup>f</sup>Bladder Cancer Center, Dana-Farber Cancer Institute, Boston, MA, USA; <sup>g</sup>Harvard Medical School, Boston, MA, USA; <sup>h</sup>Department of Urology, Netherlands Cancer Institute, Amsterdam, The Netherlands; <sup>i</sup>Department of Radiation Therapy, CHU Grenoble, Grenoble, France; <sup>j</sup>Patient Advocate, Hasselt, Belgium; <sup>k</sup>Academic Urology Unit, University of Sheffield, Sheffield, UK; <sup>l</sup>Division of Oncology/Unit of Urology, IRCCS Ospedale San Raffaele, Vita-Salute San Raffaele University, Milan, Italy; <sup>m</sup>Department of Urology, University of Bern, Inselspital, Bern, Switzerland; <sup>n</sup>Leeds Cancer Centre, St. James's University Hospital and University of Leeds, Leeds, UK; <sup>o</sup>Department of

# NPV of mpMRI

- Meta-analysis of 48 studies (9613 patients)
  - 82.4% median NPV for any cancer exclusion
  - 88.1% median NPV for clinically significant cancer exclusion

# NPV of mpMRI

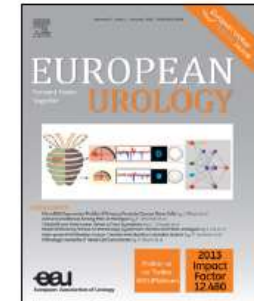- What is the impact of
  - cancer aggressiveness : higher NPV in higher treshold for clinical significance
  - cancer prevalence (statistical law)



# Rationale of mpMRI

- If mpMRI is negative (PI-RADS 1-2):  
do not biopsy (high NPV for excluding clinically significant cancer)
- If mpMRI is positive (PI-RADS 3-5):  
target biopsy needle towards mpMRI visible lesion

available at [www.sciencedirect.com](http://www.sciencedirect.com)  
journal homepage: [www.europeanurology.com](http://www.europeanurology.com)



## Collaborative Review – Prostate Cancer

# Can Clinically Significant Prostate Cancer Be Detected with Multiparametric Magnetic Resonance Imaging? A Systematic Review of the Literature

Jurgen J. Fütterer<sup>a,\*</sup>, Alberto Briganti<sup>b</sup>, Pieter De Visschere<sup>c</sup>, Mark Emberton<sup>d</sup>,  
Gianluca Giannarini<sup>e</sup>, Alex Kirkham<sup>f</sup>, Samir S. Taneja<sup>g</sup>, Harriet Thoeny<sup>h</sup>, Geert Villeirs<sup>c</sup>,  
Arnauld Villers<sup>i</sup>

<sup>a</sup>Radboud University Nijmegen Medical Centre, Nijmegen, The Netherlands; <sup>b</sup>Division of Oncology/Unit of Urology, Urological Research Institute, IRCCS Ospedale San Raffaele, Milan, Italy; <sup>c</sup>Department of Radiology, Ghent University Hospital, Ghent, Belgium; <sup>d</sup>Research Department of Urology, University College London, London, UK; <sup>e</sup>Urology Unit, Academic Medical Centre Hospital “Santa Maria della Misericordia”, Udine, Italy; <sup>f</sup>Department of Radiology, University College London Hospital, London, UK; <sup>g</sup>Division of Urologic Oncology, Department of Urology, NYU Langone Medical Center, New York, NY, USA; <sup>h</sup>Department of Radiology, Neuroradiology and Nuclear Medicine, University of Bern, Inselspital, Bern, Switzerland; <sup>i</sup>Department of Urology, Lille University Medical Centre, University Lille Nord de France, Lille, France

## Article info

*Article history:*  
Accepted January 13, 2015

## Abstract

*Context:* Detection of clinically significant prostate cancer (PCa) is a major challenge. It has been shown that multiparametric magnetic resonance imaging (mpMRI) facilitates localisation of PCa and can help in targeting prostate biopsy.

# PPV of mpMRI

- Systematic review of 12 studies (1981 patients)\*

– PPV range 34%- 68% for csPCA

- higher PPV for more aggressive tumors
- higher PPV for higher PI-RADS cutoff

	PI-RADS 3	PI-RADS 4	PI-RADS 5
Venderink**	17%	34%	67%
Mehralivand***	12%	22%	72%

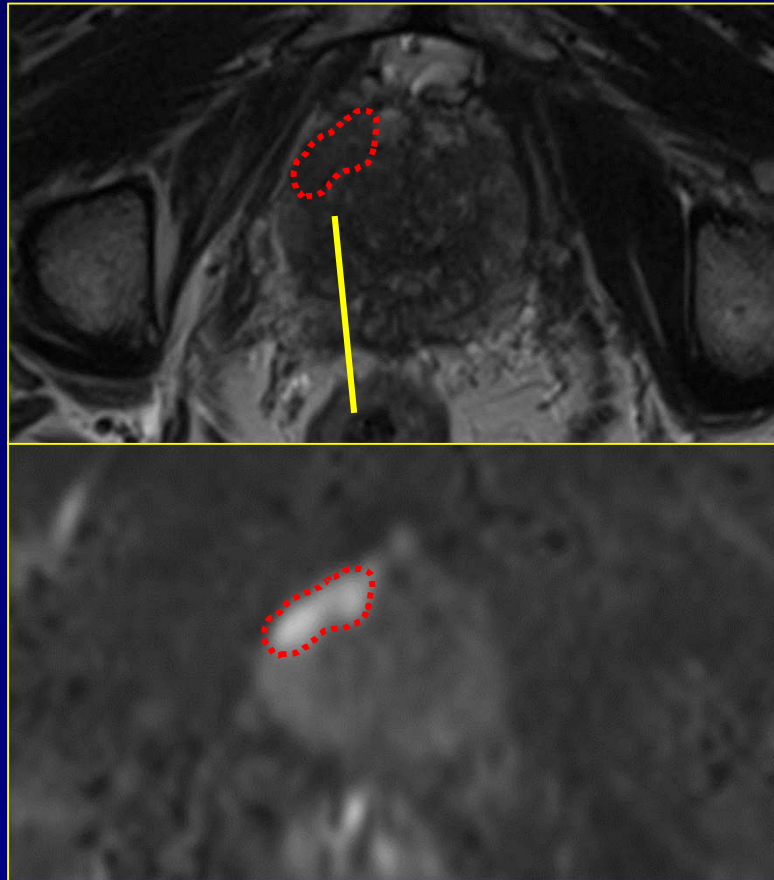
- higher PPV for more targeted biopsies

\*Fütterer, Eur Urol 2015;68:1045

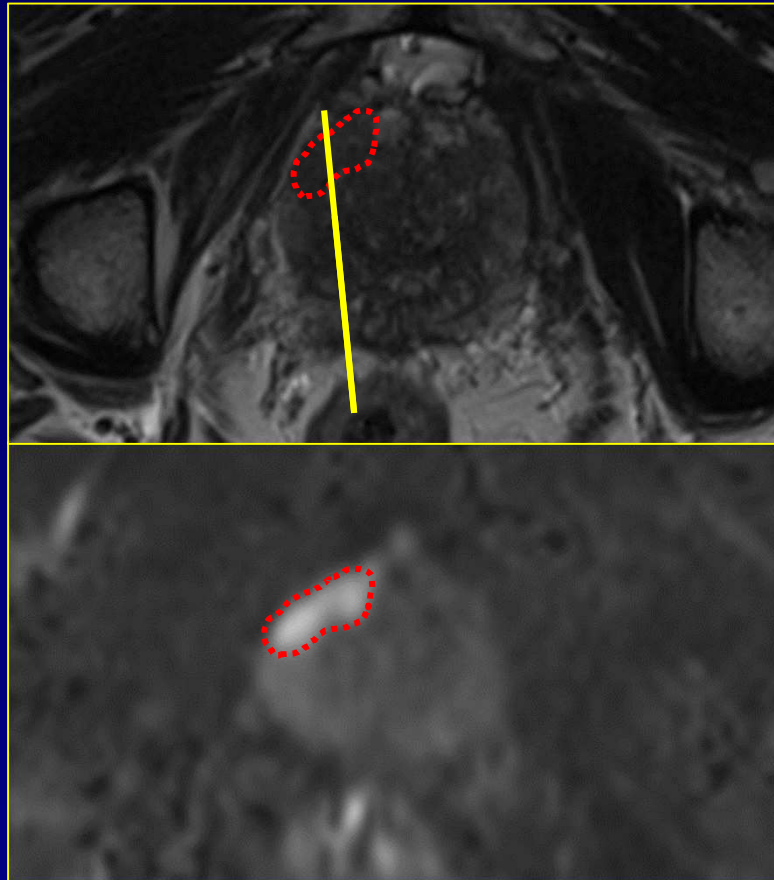
\*\*Venderink, Eur Urol 2018;73:353

\*\*\*Mehralivand, J Urol 2017;198:583

# mpMRI-guided biopsy



# mpMRI-guided biopsy



# Rationale of mpMRI

- If mpMRI is negative (PI-RADS 1-2):  
do not biopsy (high NPV for excluding clinically significant cancer)
- If mpMRI is positive (PI-RADS 3-5):  
target biopsy needle towards mpMRI visible lesion

# **Impact of clinical scenario**

# Guidelines

## Repeat biopsy

Recommendations in patients with prior negative biopsy	LE	Strength rating
Perform mpMRI before prostate biopsy.	1a	Strong
When mpMRI is positive (i.e. PI-RADS $\geq$ 3), perform targeted biopsy only.	2a	Weak
When mpMRI is negative (i.e. PI-RADS $\leq$ 2), and clinical suspicion of prostate cancer is high, perform systematic biopsy based on shared decision making with the patient.	2a	Strong

Relative sensitivity of MRI-guided biopsy versus TRUS-guided biopsy in the repeat setting is **1.45 -1.62\***

\*Schools, Eur Urol 2015;68:438  
Stabile, Prost Cancer and Prost Dis 2018;21:473

# Guidelines

## Initial biopsy

Recommendations in biopsy naïve patients	LE	Strength rating
Perform mpMRI before prostate biopsy.	1a	Weak
When mpMRI is positive (i.e. PI-RADS $\geq 3$ ), combine targeted and systematic biopsy.	2a	Strong
When mpMRI is negative (i.e. PI-RADS $\leq 2$ ), and clinical suspicion of prostate cancer is low, omit biopsy based on shared decision making with the patient.	2a	Weak

Relative sensitivity of MRI-guided biopsy versus TRUS-guided biopsy in the biopsy naïve setting is **0.97 – 1.15\***

\*Schools, Eur Urol 2015;68:438

Stabile, Prost Cancer and Prost Dis 2018;21:473



**Cochrane**  
**Library**

Cochrane Database of Systematic Reviews

## **Prostate MRI, with or without MRI-targeted biopsy, and systematic biopsy for detecting prostate cancer (Review)**

Drost FJH, Osses DF, Nieboer D, Steyerberg EW, Bangma CH, Roobol MJ, Schoots IG

## mpMRI as triage test

- In the biopsy naïve setting, use of mpMRI is 5% more likely to make the correct diagnosis (relative sensitivity **1.05**)
- In the prior negative biopsy setting, use of mpMRI is 44% more likely to make the correct diagnosis (relative sensitivity **1.44**)

\*Drost, Cochrane Database Syst Rev 2019;4:CD012663  
doi: 10.1002/14651858.CD012663.pub2

## mpMRI as triage test

- Incremental cancer detection is one thing...
- Other important questions in the screening setting:
  - how many biopsies do we deem appropriate? (“first do not harm”)
  - do we really want to find ALL cancers?

# mpMRI as triage test


ISUP 1



ISUP 2



ISUP 3-5



# Diagnostic accuracy of multi-parametric MRI and TRUS biopsy in prostate cancer (PROMIS): a paired validating confirmatory study



Hashim U Ahmed\*, Ahmed El-Shater Bosaily\*, Louise C Brown\*, Rhian Gabe, Richard Kaplan, Mahesh K Parmar, Yolanda Collaco-Moraes, Katie Ward, Richard G Hindley, Alex Freeman, Alex P Kirkham, Robert Oldroyd, Chris Parker, Mark Emberton, and the PROMIS study group†



## Summary

**Background** Men with high serum prostate specific antigen usually undergo transrectal ultrasound-guided prostate biopsy (TRUS-biopsy). TRUS-biopsy can cause side-effects including bleeding, pain, and infection. Multi-parametric magnetic resonance imaging (MP-MRI) used as a triage test might allow men to avoid unnecessary TRUS-biopsy and improve diagnostic accuracy.

**Methods** We did this multicentre, paired-cohort, confirmatory study to test diagnostic accuracy of MP-MRI and TRUS-biopsy against a reference test (template prostate mapping biopsy [TPM-biopsy]). Men with prostate-specific antigen concentrations up to 15 ng/mL, with no previous biopsy, underwent 1.5 Tesla MP-MRI followed by both TRUS-biopsy and TPM-biopsy. The conduct and reporting of each test was done blind to other test results. Clinically significant cancer was defined as Gleason score  $\geq 4+3$  or a maximum cancer core length 6 mm or longer. This study is registered on ClinicalTrials.gov, NCT01292291.

**Findings** Between May 17, 2012, and November 9, 2015, we enrolled 740 men, 576 of whom underwent 1.5 Tesla MP-MRI followed by both TRUS-biopsy and TPM-biopsy. On TPM-biopsy, 408 (71%) of 576 men had cancer with 230 (40%) of 576 patients clinically significant. For clinically significant cancer, MP-MRI was more sensitive (93%, 95% CI 88–96%) than TRUS-biopsy (48%, 42–55%;  $p < 0.0001$ ) and less specific (41%, 36–46% for MP-MRI vs 96%, 94–98% for TRUS-biopsy;  $p < 0.0001$ ). 44 (5.9%) of 740 patients reported serious adverse events, including 8 cases of sepsis.

*Lancet* 2017; 389: 815–22

Published **Online**

January 19, 2017

[http://dx.doi.org/10.1016/S0140-6736\(16\)32401-1](http://dx.doi.org/10.1016/S0140-6736(16)32401-1)

[S0140-6736\(16\)32401-1](#)

See **Comment** page 767

\*These authors contributed equally

†For a complete list of members of the PROMIS study group see appendix

Division of Surgery and Interventional Science, Faculty of Medical Sciences, University College London, London, UK  
(H Ahmed FRCS, A El-Shater Bosaily MBBCh, Prof M Emberton FRCS); Department of Urology, UCLH

ORIGINAL ARTICLE

## MRI-Targeted or Standard Biopsy for Prostate-Cancer Diagnosis

V. Kasivisvanathan, A.S. Rannikko, M. Borghi, V. Panebianco, L.A. Mynderse, M.H. Vaarala, A. Briganti, L. Budäus, G. Hellawell, R.G. Hindley, M.J. Roobol, S. Eggener, M. Ghei, A. Villers, F. Bladou, G.M. Villeirs, J. Viridi, S. Boxler, G. Robert, P.B. Singh, W. Venderink, B.A. Hadaschik, A. Ruffion, J.C. Hu, D. Margolis, S. Crouzet, L. Klotz, S.S. Taneja, P. Pinto, I. Gill, C. Allen, F. Giganti, A. Freeman, S. Morris, S. Punwani, N.R. Williams, C. Brew-Graves, J. Deeks, Y. Takwoingi, M. Emberton, and C.M. Moore, for the PRECISION Study Group Collaborators\*

### ABSTRACT

#### BACKGROUND

Multiparametric magnetic resonance imaging (MRI), with or without targeted biopsy, is an alternative to standard transrectal ultrasonography–guided biopsy for prostate-cancer detection in men with a raised prostate-specific antigen level who have not undergone biopsy. However, comparative evidence is limited.

#### METHODS

In a multicenter, randomized, noninferiority trial, we assigned men with a clinical suspicion of prostate cancer who had not undergone biopsy previously to undergo MRI, with or without targeted biopsy, or standard transrectal ultrasonography–guided biopsy. Men in the MRI-targeted biopsy group underwent a targeted biopsy (without standard biopsy cores) if the MRI was suggestive of prostate cancer; men whose MRI results were not suggestive of prostate cancer were not offered biopsy.

The authors' full names, academic degrees, and affiliations are listed in the Appendix. Address reprint requests to Dr. Kasivisvanathan at the Division of Surgery and Interventional Science, UCL, 3rd Fl., Charles Bell House, 43-45 Foley St., London W1W 7TS, United Kingdom, or at [veeru.kasi@ucl.ac.uk](mailto:veeru.kasi@ucl.ac.uk).

\*A complete list of members of the PRECISION Study Group is provided in the Supplementary Appendix, available at [NEJM.org](http://NEJM.org).

This article was published on March 19, 2019.

available at [www.sciencedirect.com](http://www.sciencedirect.com)  
journal homepage: [www.europeanurology.com](http://www.europeanurology.com)



## Platinum Priority – Prostate Cancer – Editor's Choice

*Editorial by Derek J. Rosario, Thomas J. Walton and Steven J. Kennish on pp. 579–581 of this issue*

# Head-to-head Comparison of Transrectal Ultrasound-guided Prostate Biopsy Versus Multiparametric Prostate Resonance Imaging with Subsequent Magnetic Resonance-guided Biopsy in Biopsy-naïve Men with Elevated Prostate-specific Antigen: A Large Prospective Multicenter Clinical Study

*Marloes van der Leest<sup>a</sup>, Erik Cornel<sup>b</sup>, Bas Israël<sup>a</sup>, Rianne Hendriks<sup>c</sup>, Anwar R. Padhani<sup>d</sup>, Martijn Hoogenboom<sup>a</sup>, Patrik Zamecnik<sup>a</sup>, Dirk Bakker<sup>b</sup>, Anglita Yanti Setiasti<sup>e</sup>, Jeroen Veltman<sup>f</sup>, Huib van den Hout<sup>f</sup>, Hans van der Lelij<sup>g</sup>, Inge van Oort<sup>c</sup>, Sjoerd Klaver<sup>h</sup>, Frans Debruyne<sup>i</sup>, Michiel Sedelaar<sup>c</sup>, Gerjon Hannink<sup>j</sup>, Maroeska Rovers<sup>j</sup>, Christina Hulsbergen-van de Kaa<sup>e,†</sup>, Jelle O. Barentsz<sup>a,†,\*</sup>*

<sup>a</sup> Department of Radiology and Nuclear Medicine, Radboud University Medical Center, Nijmegen, The Netherlands; <sup>b</sup> Department of Urology, Ziekenhuis Groep Twente, Almelo-Hengelo, The Netherlands; <sup>c</sup> Department of Urology, Radboud University Medical Center, Nijmegen, The Netherlands; <sup>d</sup> Paul Strickland Scanner Centre, Mount Vernon Cancer Centre, Northwood, UK; <sup>e</sup> Department of Pathology, Radboud University Medical Center, Nijmegen, The Netherlands; <sup>f</sup> Department of Radiology, Ziekenhuis Groep Twente, Almelo-Hengelo, The Netherlands; <sup>g</sup> Department of Radiology and Nuclear Medicine, Maasstad Hospital,



# Use of prostate systematic and targeted biopsy on the basis of multiparametric MRI in biopsy-naive patients (MRI-FIRST): a prospective, multicentre, paired diagnostic study

Olivier Rouvière, Philippe Puech, Raphaële Renard-Penna, Michel Claudon, Catherine Roy, Florence Mège-Lechevallier, Myriam Decaussin-Petrucci, Marine Dubreuil-Chambardel, Laurent Magaud, Laurent Remontet, Alain Ruffion, Marc Colombel, Sébastien Crouzet, Anne-Marie Schott, Laurent Lemaître, Muriel Rabilloud, Nicolas Grenier, for the MRI-FIRST Investigators\*

## Summary

*Lancet Oncol* 2019; 20: 100–09

Published Online  
November 20, 2018  
[http://dx.doi.org/10.1016/S1470-2045\(18\)30569-2](http://dx.doi.org/10.1016/S1470-2045(18)30569-2)

See [Comment](#) page 9

\*All MRI-FIRST investigators are listed in the appendix

Service d'Imagerie Urinaire et Vasculaire (Prof O Rouvière MD, M Dubreuil-Chambardel PhD), Service d'Anatomo-Pathologie (F Mège-Lechevallier MD), and Service d'Urologie (Prof M Colombel MD, Prof S Crouzet MD), Hôpital Edouard Herriot, Service d'Urologie (Prof A Ruffion MD), Service d'Anatomo-Pathologie (M Decaussin-Petrucci MD), Center Hospitalier Lyon Sud, Pôle de Santé Publique (L Magaud PhD, Prof A-M Schott MD), and Service de Biostatistique et Bioinformatique (L Remontet MD, M Rabilloud MD), Hospices Civils de Lyon, Lyon, France; Faculté de Médecine Lyon Est

**Background** Whether multiparametric MRI improves the detection of clinically significant prostate cancer and avoids the need for systematic biopsy in biopsy-naive patients remains controversial. We aimed to investigate whether using this approach before biopsy would improve detection of clinically significant prostate cancer in biopsy-naive patients.

**Methods** In this prospective, multicentre, paired diagnostic study, done at 16 centres in France, we enrolled patients aged 18–75 years with prostate-specific antigen concentrations of 20 ng/mL or less, and with stage T2c or lower prostate cancer. Eligible patients had been referred for prostate multiparametric MRI before a first set of prostate biopsies, with a planned interval of less than 3 months between MRI and biopsies. An operator masked to multiparametric MRI results did a systematic biopsy by obtaining 12 systematic cores and up to two cores targeting hypoechoic lesions. In the same patient, another operator targeted up to two lesions seen on MRI with a Likert score of 3 or higher (three cores per lesion) using targeted biopsy based on multiparametric MRI findings. Patients with negative multiparametric MRI (Likert score  $\leq 2$ ) had systematic biopsy only. The primary outcome was the detection of clinically significant prostate cancer of International Society of Urological Pathology grade group 2 or higher (csPCa-A), analysed in all patients who received both systematic and targeted biopsies and whose results from both were available for pathological central review, including patients who had protocol deviations. This study is registered with ClinicalTrials.gov, number NCT02485379, and is closed to new participants.

**Findings** Between July 15, 2015, and Aug 11, 2016, we enrolled 275 patients. 24 (9%) were excluded from the analysis. 53 (21%) of 251 analysed patients had negative (Likert  $\leq 2$ ) multiparametric MRI. csPCa-A was detected in 94 (37%) of 251 patients. 13 (14%) of these 94 patients were diagnosed by systematic biopsy only, 19 (20%) by targeted biopsy only, and 62 (66%) by both techniques. Detection of csPCa-A by systematic biopsy (29.9%, 95% CI 24.3–36.0) and targeted biopsy (32.3%, 26.5–38.4) did not differ significantly ( $p=0.38$ ). csPCa-A would have been missed in 5.2% (95% CI 2.8–8.7) of patients had systematic biopsy not been done, and in 7.6% (4.6–11.6) of patients had targeted biopsy not been done. Four grade 3 post-biopsy adverse events were reported (3 cases of prostatitis, and 1 case of urinary retention with haematuria).



**Cochrane**  
**Library**

Cochrane Database of Systematic Reviews

## **Prostate MRI, with or without MRI-targeted biopsy, and systematic biopsy for detecting prostate cancer (Review)**

Drost FJH, Osses DF, Nieboer D, Steyerberg EW, Bangma CH, Roobol MJ, Schoots IG

# mpMRI as triage test?

	PROMIS	PRECISION	4M	MRI First	COCHRANE

PROMIS - Ahmed, Lancet 2017;389:815

PRECISION - Kasivisvanathan, NEJM 2018;378:1767

4M – van der Leest, Eur Urol 2019;75:570

MRI First – Lancet Oncol 2019; 20: 100–09

Cochrane Review – Drost, Cochrane Database Syst Rev 2019;4:CD012663

doi: 10.1002/14651858.CD012663.pub2

# mpMRI as triage test?

	PROMIS	PRECISION	4M	MRI First	COCHRANE
# patients	576	500	626	251	-

PROMIS - Ahmed, Lancet 2017;389:815

PRECISION - Kasivisvanathan, NEJM 2018;378:1767

4M – van der Leest, Eur Urol 2019;75:570

MRI First – Lancet Oncol 2019; 20: 100–09

Cochrane Review – Drost, Cochrane Database Syst Rev 2019;4:CD012663

doi: 10.1002/14651858.CD012663.pub2

# mpMRI as triage test?

	PROMIS	PRECISION	4M	MRI First	COCHRANE
# patients	576	500	626	251	-
PSA	≤ 15 ng/mL	≤ 20 ng/mL	≥ 3 ng/mL	≤ 20 ng/mL	-

PROMIS - Ahmed, Lancet 2017;389:815

PRECISION - Kasivisvanathan, NEJM 2018;378:1767

4M – van der Leest, Eur Urol 2019;75:570

MRI First – Lancet Oncol 2019; 20: 100–09

Cochrane Review – Drost, Cochrane Database Syst Rev 2019;4:CD012663

doi: 10.1002/14651858.CD012663.pub2

# mpMRI as triage test?

	PROMIS	PRECISION	4M	MRI First	COCHRANE
# patients	576	500	626	251	-
PSA	≤ 15 ng/mL	≤ 20 ng/mL	≥ 3 ng/mL	≤ 20 ng/mL	-
Biopsies					

PROMIS - Ahmed, Lancet 2017;389:815

PRECISION - Kasivisvanathan, NEJM 2018;378:1767

4M – van der Leest, Eur Urol 2019;75:570

MRI First – Lancet Oncol 2019; 20: 100–09

Cochrane Review – Drost, Cochrane Database Syst Rev 2019;4:CD012663

doi: 10.1002/14651858.CD012663.pub2

# mpMRI as triage test?

	PROMIS	PRECISION	4M	MRI First	COCHRANE
# patients	576	500	626	251	-
PSA	≤ 15 ng/mL	≤ 20 ng/mL	≥ 3 ng/mL	≤ 20 ng/mL	-
Biopsies	-27%				

PROMIS - Ahmed, Lancet 2017;389:815

PRECISION - Kasivisvanathan, NEJM 2018;378:1767

4M – van der Leest, Eur Urol 2019;75:570

MRI First – Lancet Oncol 2019; 20: 100–09

Cochrane Review – Drost, Cochrane Database Syst Rev 2019;4:CD012663

doi: 10.1002/14651858.CD012663.pub2

# mpMRI as triage test?

	PROMIS	PRECISION	4M	MRI First	COCHRANE
# patients	576	500	626	251	-
PSA	≤ 15 ng/mL	≤ 20 ng/mL	≥ 3 ng/mL	≤ 20 ng/mL	-
Biopsies	-27%	-28%			

PROMIS - Ahmed, Lancet 2017;389:815

PRECISION - Kasivisvanathan, NEJM 2018;378:1767

4M – van der Leest, Eur Urol 2019;75:570

MRI First – Lancet Oncol 2019; 20: 100–09

Cochrane Review – Drost, Cochrane Database Syst Rev 2019;4:CD012663

doi: 10.1002/14651858.CD012663.pub2

# mpMRI as triage test?

	PROMIS	PRECISION	4M	MRI First	COCHRANE
# patients	576	500	626	251	-
PSA	≤ 15 ng/mL	≤ 20 ng/mL	≥ 3 ng/mL	≤ 20 ng/mL	-
Biopsies	-27%	-28%	-49%		

PROMIS - Ahmed, Lancet 2017;389:815

PRECISION - Kasivisvanathan, NEJM 2018;378:1767

4M – van der Leest, Eur Urol 2019;75:570

MRI First – Lancet Oncol 2019; 20: 100–09

Cochrane Review – Drost, Cochrane Database Syst Rev 2019;4:CD012663

doi: 10.1002/14651858.CD012663.pub2

# mpMRI as triage test?

	PROMIS	PRECISION	4M	MRI First	COCHRANE
# patients	576	500	626	251	-
PSA	≤ 15 ng/mL	≤ 20 ng/mL	≥ 3 ng/mL	≤ 20 ng/mL	-
Biopsies	-27%	-28%	-49%	-18%	

PROMIS - Ahmed, Lancet 2017;389:815

PRECISION - Kasivisvanathan, NEJM 2018;378:1767

4M – van der Leest, Eur Urol 2019;75:570

MRI First – Lancet Oncol 2019; 20: 100–09

Cochrane Review – Drost, Cochrane Database Syst Rev 2019;4:CD012663

doi: 10.1002/14651858.CD012663.pub2

# mpMRI as triage test?

	PROMIS	PRECISION	4M	MRI First	COCHRANE
# patients	576	500	626	251	-
PSA	≤ 15 ng/mL	≤ 20 ng/mL	≥ 3 ng/mL	≤ 20 ng/mL	-
Biopsies	-27%	-28%	-49%	-18%	
Insignificant cancers	-5%	-13%	-11%	-13%	

PROMIS - Ahmed, Lancet 2017;389:815

PRECISION - Kasivisvanathan, NEJM 2018;378:1767

4M – van der Leest, Eur Urol 2019;75:570

MRI First – Lancet Oncol 2019; 20: 100–09

Cochrane Review – Drost, Cochrane Database Syst Rev 2019;4:CD012663

doi: 10.1002/14651858.CD012663.pub2

# mpMRI as triage test?

	PROMIS	PRECISION	4M	MRI First	COCHRANE
# patients	576	500	626	251	-
PSA	≤ 15 ng/mL	≤ 20 ng/mL	≥ 3 ng/mL	≤ 20 ng/mL	-
Biopsies	-27%	-28%	-49%	-18%	
Insignificant cancers	-5%	-13%	-11%	-13%	
Significant cancers	+18%	+12%	+2%	+2%	

PROMIS - Ahmed, Lancet 2017;389:815

PRECISION - Kasivisvanathan, NEJM 2018;378:1767

4M – van der Leest, Eur Urol 2019;75:570

MRI First – Lancet Oncol 2019; 20: 100–09

Cochrane Review – Drost, Cochrane Database Syst Rev 2019;4:CD012663

doi: 10.1002/14651858.CD012663.pub2

# mpMRI as triage test?

	PROMIS	PRECISION	4M	MRI First	COCHRANE
# patients	576	500	626	251	-
PSA	≤ 15 ng/mL	≤ 20 ng/mL	≥ 3 ng/mL	≤ 20 ng/mL	-
Biopsies	-27%	-28%	-49%	-18%	<b>-33%</b>
Insignificant cancers	-5%	-13%	-11%	-13%	
Significant cancers	+18%	+12%	+2%	+2%	

PROMIS - Ahmed, Lancet 2017;389:815

PRECISION - Kasivisvanathan, NEJM 2018;378:1767

4M – van der Leest, Eur Urol 2019;75:570

MRI First – Lancet Oncol 2019; 20: 100–09

Cochrane Review – Drost, Cochrane Database Syst Rev 2019;4:CD012663

doi: 10.1002/14651858.CD012663.pub2

# mpMRI as triage test?

	PROMIS	PRECISION	4M	MRI First	COCHRANE
# patients	576	500	626	251	-
PSA	≤ 15 ng/mL	≤ 20 ng/mL	≥ 3 ng/mL	≤ 20 ng/mL	-
Biopsies	-27%	-28%	-49%	-18%	<b>-33%</b>
Insignificant cancers	-5%	-13%	-11%	-13%	<b>-8%</b>
Significant cancers	+18%	+12%	+2%	+2%	

PROMIS - Ahmed, Lancet 2017;389:815

PRECISION - Kasivisvanathan, NEJM 2018;378:1767

4M – van der Leest, Eur Urol 2019;75:570

MRI First – Lancet Oncol 2019; 20: 100–09

Cochrane Review – Drost, Cochrane Database Syst Rev 2019;4:CD012663

doi: 10.1002/14651858.CD012663.pub2

# mpMRI as triage test?

	PROMIS	PRECISION	4M	MRI First	COCHRANE
# patients	576	500	626	251	-
PSA	≤ 15 ng/mL	≤ 20 ng/mL	≥ 3 ng/mL	≤ 20 ng/mL	-
Biopsies	-27%	-28%	-49%	-18%	<b>-33%</b>
Insignificant cancers	-5%	-13%	-11%	-13%	<b>-8%</b>
Significant cancers	+18%	+12%	+2%	+2%	<b>+2%</b>

PROMIS - Ahmed, Lancet 2017;389:815

PRECISION - Kasivisvanathan, NEJM 2018;378:1767

4M – van der Leest, Eur Urol 2019;75:570

MRI First – Lancet Oncol 2019; 20: 100–09

Cochrane Review – Drost, Cochrane Database Syst Rev 2019;4:CD012663

doi: 10.1002/14651858.CD012663.pub2

## mpMRI as triage test?

- More cancers detected than with TRUS-guided biopsy
  - in prior negative biopsy setting (+40%)
  - in biopsy naïve setting (+5%)
- Less biopsies overall
  - in “standard” centers: –27%
  - in expert centers: –49%

## mpMRI as triage test?

- Less insignificant cancers (ISUP 1):  
-8%
- More significant cancers (ISUP 2-5):  
+2%

bpMRI as triage test?



Original Investigation | Urology

# Assessment of the Diagnostic Accuracy of Biparametric Magnetic Resonance Imaging for Prostate Cancer in Biopsy-Naive Men

## The Biparametric MRI for Detection of Prostate Cancer (BIDOC) Study

Lars Boesen, MD, PhD; Nis Nørgaard, MD; Vibeke Løgager, MD; Ingegerd Balslev, MD; Rasmus Bisbjerg, MD; Karen-Cecilie Thestrup, MD; Mads D. Winther; Henrik Jakobsen, MD; Henrik S. Thomsen, DMC

### Abstract

**IMPORTANCE** Multiparametric magnetic resonance imaging (MRI) enhances detection and risk stratification for significant prostate cancer but is time-consuming (approximately 40 minutes) and expensive. Rapid and simpler (approximately 15-minute) biparametric MRI (bpMRI) using fewer scan sequences could be implemented as a prostate MRI triage test on a larger scale before performing biopsies.

**OBJECTIVES** To assess the diagnostic accuracy and negative predictive value (NPV) of a novel bpMRI method in biopsy-naive men in detecting and ruling out significant prostate cancer in confirmatory biopsies.

**DESIGN, SETTING, AND PARTICIPANTS** A single-institutional, paired, prospective cohort study of biopsy-naive men with clinical suspicion of prostate cancer from November 1, 2015, to June 15, 2017.

**INTERVENTIONS** All patients underwent bpMRI (T2-weighted and diffusion-weighted imaging) followed by standard transrectal ultrasound-guided biopsies (all men) and targeted biopsies of men with suspicious bpMRI findings.

**MAIN OUTCOMES AND MEASURES** Suspicion grades of bpMRI, biopsy results, and NPV of bpMRI

### Key Points

**Question** What are the diagnostic accuracy and negative predictive value of novel biparametric magnetic resonance imaging (MRI) in biopsy-naive men in detecting and ruling out significant prostate cancer?

**Findings** In this cohort study of 1020 men who underwent both biparametric targeted and standard transrectal ultrasound-guided biopsies, low-suspicion biparametric MRI had a high negative predictive value (97%) in ruling out significant prostate cancer on confirmatory biopsies.

**Meaning** The biparametric MRI used as a triage test in this study was associated with improved prostate cancer risk stratification and may be used to

# bpMRI as triage test?

- Bidoc trial: prospective paired-cohort study, PSA  $\geq$  4 ng/mL or abnormal DRE
  - 1020 biopsy-naïve men
  - bpMRI @ 3T (15 mins)
    - ax/sag T2w + ax DWI (b0, b100, b800, b2000)
    - modified PI-RADS: DWI 3 final
  - standard biopsy + bpMRI-targeted biopsy as reference

# bpMRI as triage test?

	BIDOC					
# patients	1020					
PSA	≥ 4 ng/mL					
Biopsies						
Insignificant cancers						
Significant cancers						

# bpMRI as triage test?

	BIDOC					
# patients	1020					
PSA	≥ 4 ng/mL					
Biopsies	-30%					
Insignificant cancers						
Significant cancers						

# bpMRI as triage test?

	BIDOC					
# patients	1020					
PSA	≥ 4 ng/mL					
Biopsies	-30%					
Insignificant cancers	-40%					
Significant cancers						

# bpMRI as triage test?

	BIDOC					
# patients	1020					
PSA	≥ 4 ng/mL					
Biopsies	-30%					
Insignificant cancers	-40%					
Significant cancers	+11%					

# bpMRI as triage test?

	BIDOC	PROMIS	PRECISION	4M	MRI First	Cochrane
# patients	1020	576	500	626	251	-
PSA	≥ 4 ng/mL	≤ 15 ng/mL	≤ 20 ng/mL	≥ 3 ng/mL	≤ 20 ng/mL	-
Biopsies	-30%	-27%	-28%	-49%	-18%	-33%
Insignificant cancers	-40%	-5%	-13%	-11%	-13%	-8%
Significant cancers	+11%	+18%	+12%	+2%	+2%	+2%

PROMIS - Ahmed, Lancet 2017;389:815

PRECISION - Kasivisvanathan, NEJM 2018;378:1767

4M – van der Leest, Eur Urol 2019;75:570

MRI First – Lancet Oncol 2019; 20: 100–09

Cochrane Review – Drost, Cochrane Database Syst Rev 2019;4:CD012663

doi: 10.1002/14651858.CD012663.pub2

# bpMRI as triage test?

- Yes

# bpMRI as triage test?

- Yes, but...
  - only in case of high quality DWI
  - not in case of recurrence detection



**STAGING**

# Prostate Cancer Staging

- Gold standard?
  - Clinical Predictors :
    - Clinical stage (DRE)
    - Gleason score
    - Serum PSA (PSA-density)
    - Transrectal core needle biopsy variables:
      - % involved cores among total number > 15%
      - % tumor in involved cores
      - presence of perineural invasion

# Prostate Cancer Staging

- Gold standard?
  - Integration into nomograms...
    - Partin's tables (ECE and SVI)\*
    - Kattan nomogram (SVI)\*\*
  - ... or formulas
    - Roach and Diaz formula (ECE and SVI)\*\*\*

\*Makarov, Urology 2007;69:1095

\*\*Koh, J Urol 2003;170:1203

\*\*\*Roach, J Urol 1993;150:1923 - Diaz, IJROBH 1994;30:323

# Prostate Cancer Staging

- Gold standard?
  - Result: % chance of T3-T4 disease
  - Accuracy in predicting ECE and SVI :  
ROC 0.79-0.82\*
  - Drawbacks:
    - only a %, no individual information
    - no anatomical information (side? size?)\*\*

\*Augustin, J Urol 2004;171:177 - Graefen, Eur Urol 2003;43:6  
Wang, Radiology 2006;238:597

\*\*Wang, Radiology 2004;232:133

# Prostate Cancer Staging

- Why not use MRI?
  - better identification of ECE and SVI?
  - better localization of affected area?
  - better treatment choice?

**HOW GOOD  
ARE WE?**

# Staging accuracy

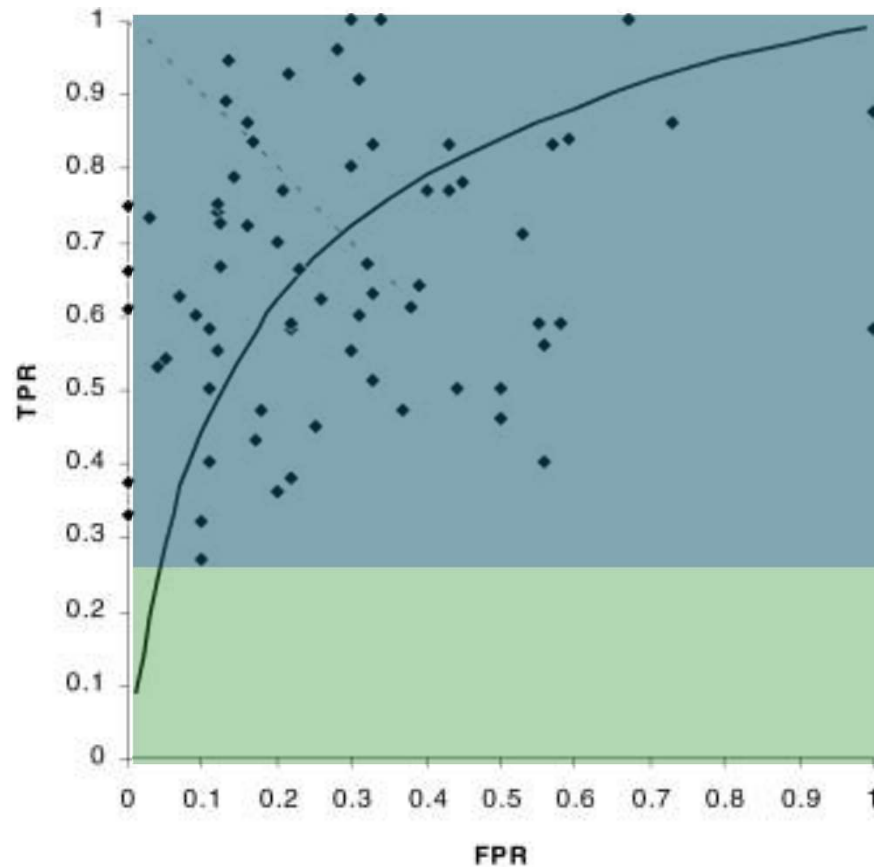
Eur Radiol (2002) 12:2294–2302  
DOI 10.1007/s00330-002-1389-z

UROGENITAL

Marc R. Engelbrecht  
Gerrit J. Jager  
Robert J. Laheij  
André L. M. Verbeek  
H. J. van Lier  
Jelle O. Barentsz

**Local staging of prostate cancer  
using magnetic resonance imaging:  
a meta-analysis**

# Staging accuracy



**Sensitivity**  
26%-100%

**Specificity**  
0%-100%


# Staging accuracy

EUROPEAN UROLOGY 70 (2016) 233–245

available at [www.sciencedirect.com](http://www.sciencedirect.com)  
journal homepage: [www.europeanurology.com](http://www.europeanurology.com)



European Association of Urology



Platinum Priority – Review – Prostate Cancer

*Editorial by Anwar R. Padhani, Giuseppe Petralia and Francesco Sanguedolce on pp. 246–247 of this issue*

## Accuracy of Magnetic Resonance Imaging for Local Staging of Prostate Cancer: A Diagnostic Meta-analysis

*Maarten de Rooij<sup>\*</sup>, Esther H.J. Hamoen, J. Alfred Witjes, Jelle O. Barentsz, Maroeska M. Rovers*

*Radboud University Medical Centre, Radboud Institute for Health Sciences, Nijmegen, The Netherlands*

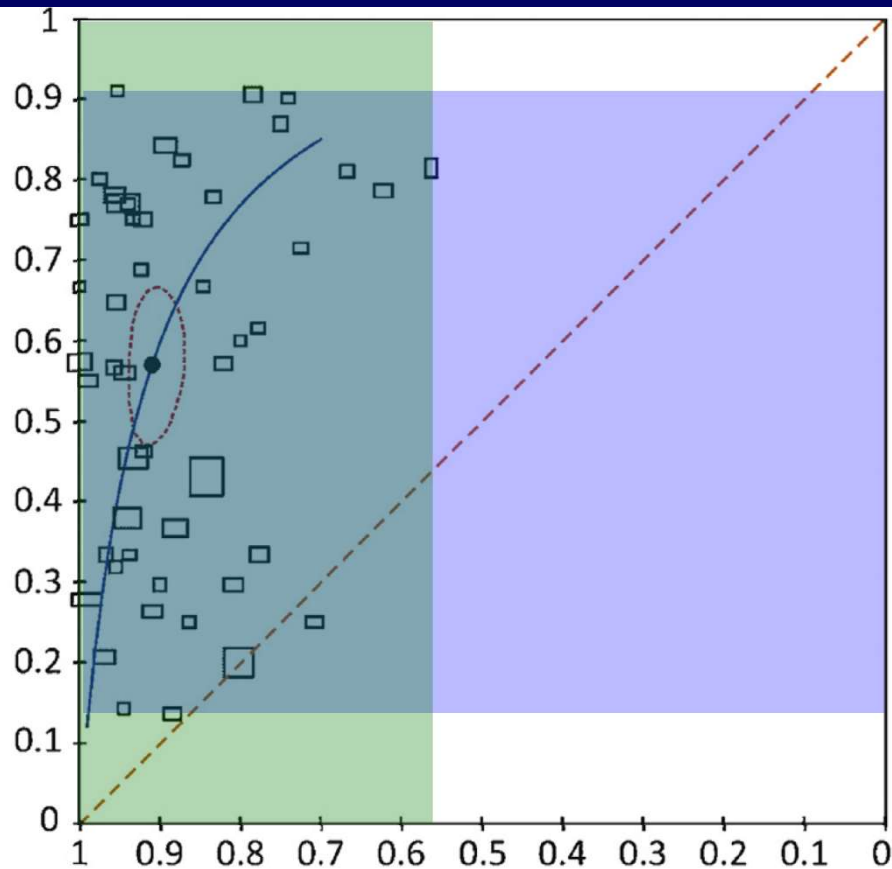
### Article info

*Article history:*

### Abstract

*Context:* Correct assessment of tumour stage is crucial for prostate cancer (PCa) man-

# Staging accuracy



**Sensitivity**

14%-91%

**Specificity**

56%-100%

# Staging accuracy

## CCO GUIDELINES

### Multiparametric magnetic resonance imaging for pre-treatment local staging of prostate cancer: A Cancer Care Ontario clinical practice guideline

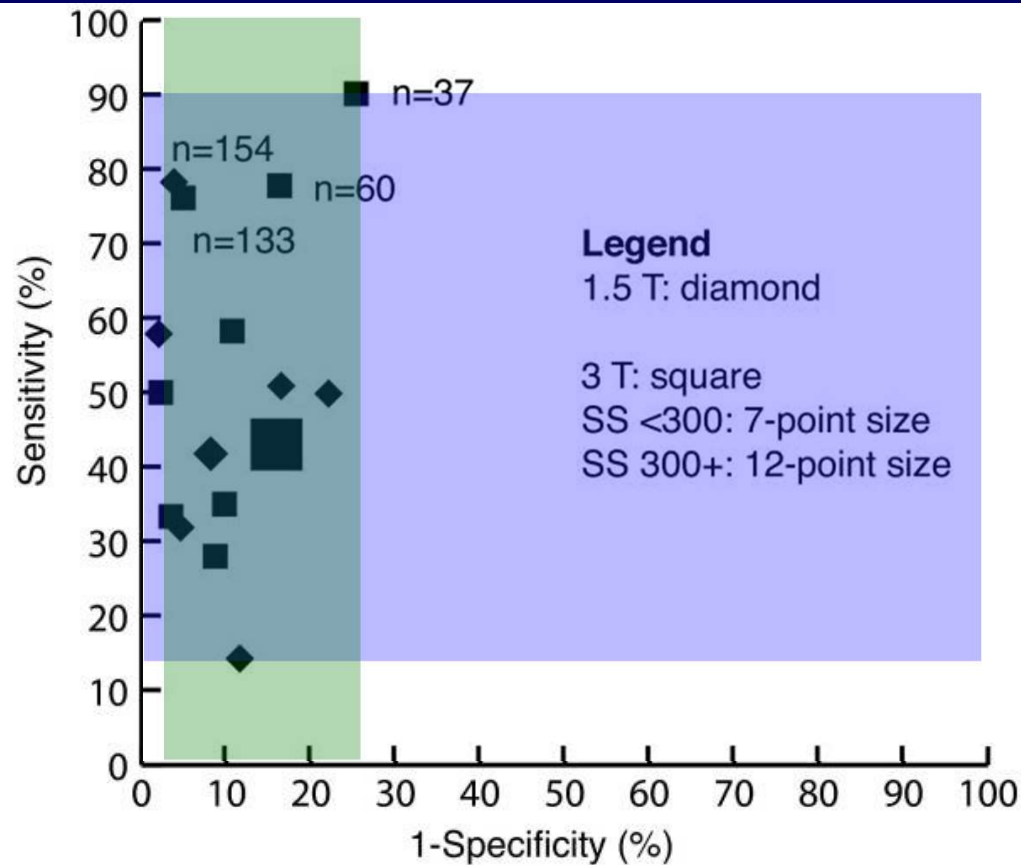
*Jennifer Salerno, PhD;<sup>1</sup> Antonio Finelli, MD;<sup>2</sup> Chris Morash, MD;<sup>3</sup> Scott C. Morgan, MD;<sup>3</sup> Nicholas Power, MD;<sup>4</sup> Nichola Schieda, MD;<sup>5</sup> Masoom A. Haider, MD<sup>6</sup>*

<sup>1</sup>McMaster University, Department of Oncology and Program in Evidence-Based Care, Cancer Care Ontario, Hamilton, ON, Canada; <sup>2</sup>Princess Margaret Hospital, Toronto, ON, Canada; <sup>3</sup>The Ottawa Hospital, Ottawa, ON, Canada; <sup>4</sup>Western University, London, ON, Canada; <sup>5</sup>Department of Medical Imaging, The Ottawa Hospital, Ottawa, ON, Canada; <sup>6</sup>Sunnybrook Health Sciences Centre, University of Toronto, ON, Canada

Cite as: *Can Urol Assoc J* 2016;10(9-10):E332-9. <http://dx.doi.org/10.5489/cuaj.3823>  
Published online October 13

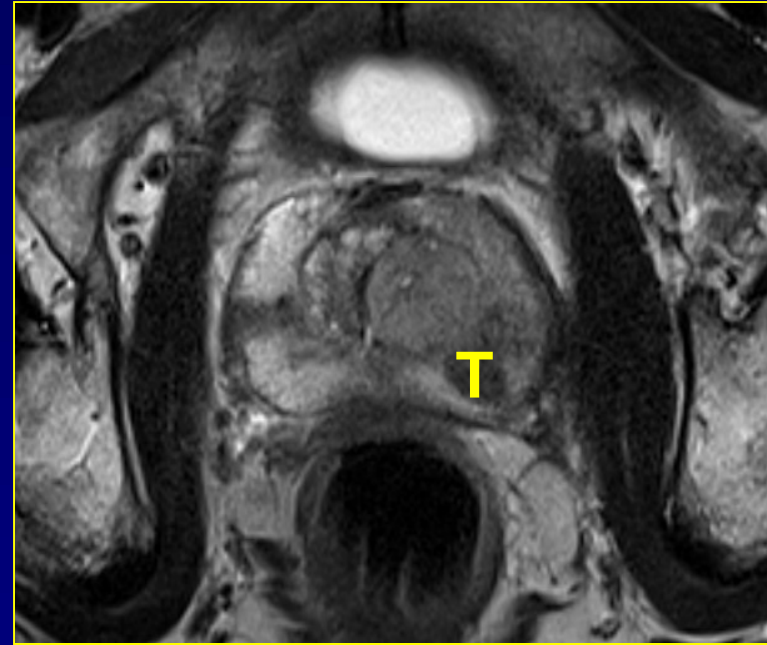
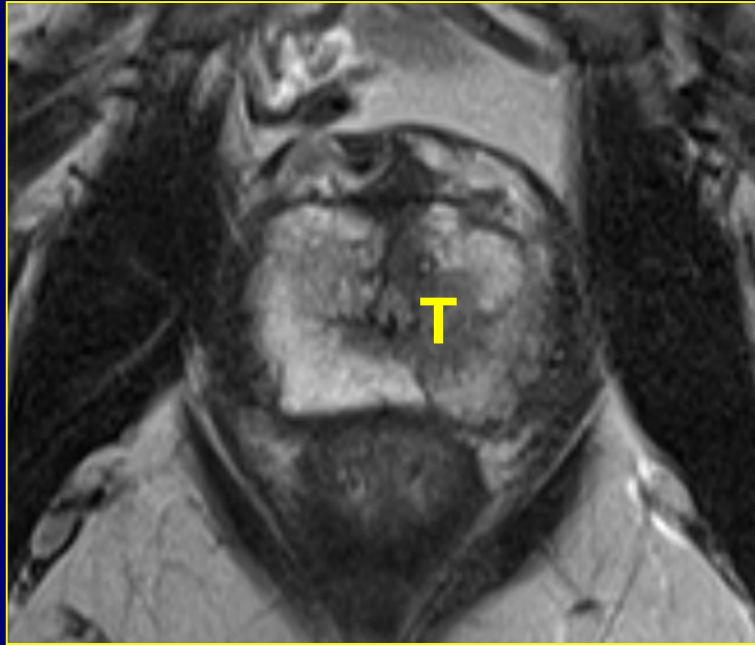
**Introduction**

# Staging accuracy



**WHAT IS  
GOING WRONG?**

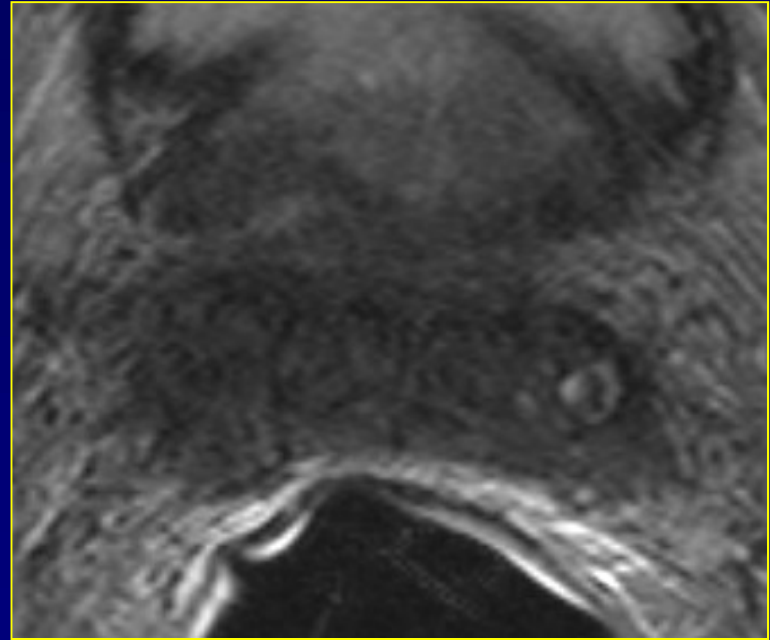
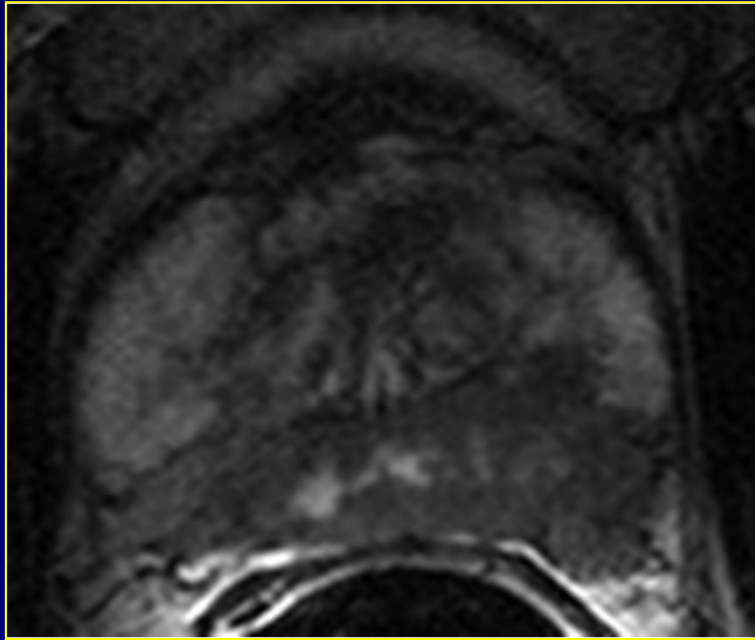
# T-stage?



iT2a

Easy Diagnosis

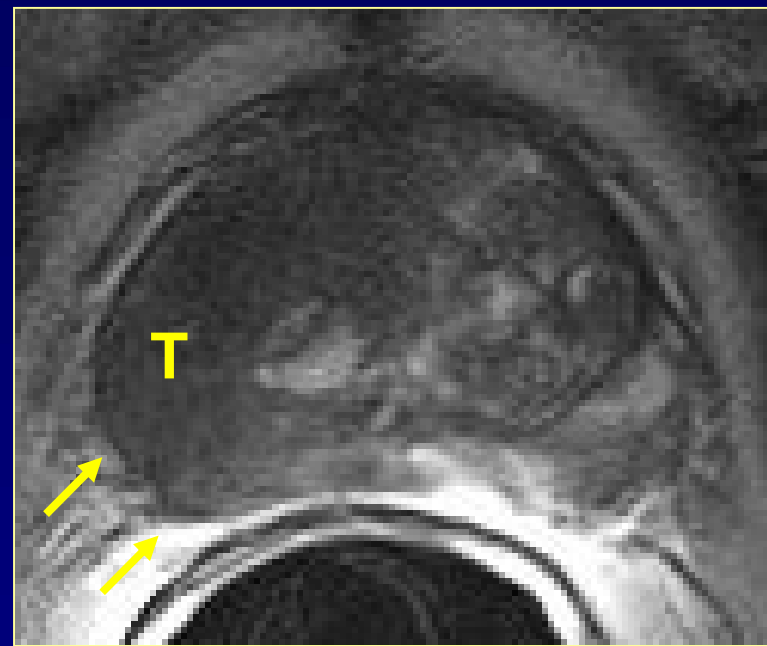
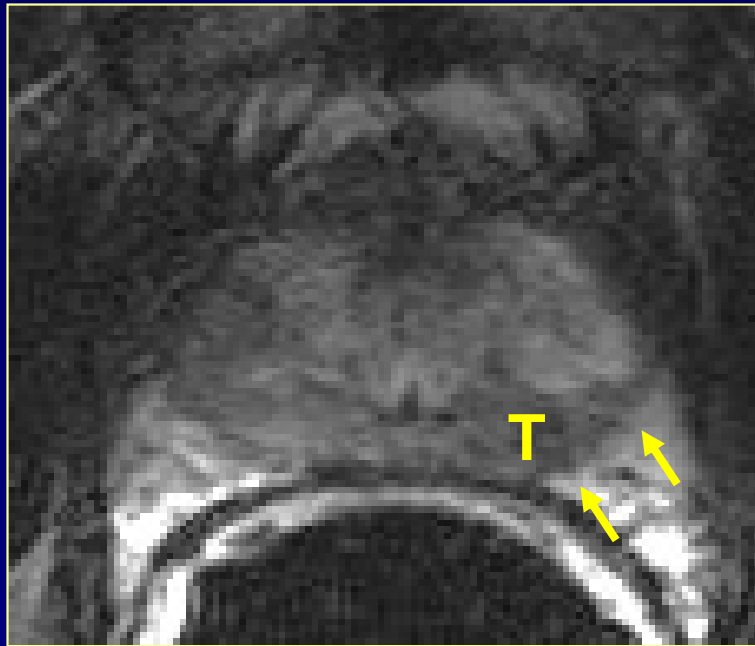
# T-stage?



iT3

Easy Diagnosis

# T-stage?



Slight capsular irregularity  
Slight capsular undulation

# Diagnostic criteria

- Vast amount of literature

Tempany, Radiology 1991;181:107

Tempany, Radiology 1994;192:47

Presti, AJR 1996;166:103

Bartolozzi, Eur Radiol 1996;6:339

Yu, Radiology 1997;202:697

Yu, Radiology 1999;213:481

Padhani, Clin Radiol 2000;55:99

Cornud, Radiology 2002;224:203

Nakashima, Urology 2004;64:101

Quayyum, AJR 2004;183:1079

Wang, Radiology 2004;232:133

Sala, Radiology 2006;238:929

Heijmink, Radiology 2007;244:184

Fütterer, Eur J Radiol 2007;63:328

Cornud, Eur J Radiol 2012;81:e591

Soylu, Diagn Interv Radiol 2012;18:365

Xylinas, World J Urol 2013;31:881



# Diagnostic criteria

## SVI

- Focal hypointense luminal replacement
- Asymmetric SI enhancement within lumen
- Enlarged ejaculatory ducts with low SI
- Non-contiguous areas of late and SI
- Expanded low SI areas of late and SI
- Thickening of SV walls only when positive biopsy at one/both prostatic bases
- Focal or diffuse thickening of SV walls
- Thickening of SV walls only when positive biopsy at one/both prostatic bases
- Lack of angle between SV and ureter
- Thickening of SV walls only when positive biopsy at one/both prostatic bases
- Low SI within SV causing thickening of SV walls
- Thickening of SV walls only when positive biopsy at one/both prostatic bases
- Obliteration of SV
- Thickening of SV walls only when positive biopsy at one/both prostatic bases
- Nonvisualization of normal architecture in the SV of seminal vesicles
- Direct extension of low SI tumor from prostatic bases
- Filling defect within SV of seminal vesicles

# Technical parameters

Characteristic	AUC ECE		AUC SVI		AUC T3	
1 plane	0.50±0.21	<i>n</i> =22	0.43±0.19	<i>n</i> =16	0.52±0.10	<i>n</i> =33
≥2 planes	0.57±0.23	<i>n</i> =49	0.66±0.22	<i>n</i> =41	0.64±0.13	<i>n</i> =26
Missing value	0.62±0.14	<i>n</i> =21	0.70±0.15	<i>n</i> =23	0.68±0.12	<i>n</i> =24
		<i>p</i> <0.01		<i>p</i> =0.012		<i>p</i> <0.001
Spin echo			0.49±0.24	<i>n</i> =22	0.55±0.12	<i>n</i> =39
Turbo spin echo			0.69±0.19	<i>n</i> =44	0.65±0.14	<i>n</i> =33
Missing value			0.60±0.16	<i>n</i> =14	0.66±0.09	<i>n</i> =11
		NS		<i>p</i> =0.05		<i>p</i> <0.01
Without endorectal coil			0.58±0.23	<i>n</i> =27	0.54±0.11	<i>n</i> =29
With endorectal coil			0.67±0.21	<i>n</i> =46	0.65±0.13	<i>n</i> =41
Missing value			0.51±0.21	<i>n</i> =7	0.60±0.12	<i>n</i> =13
		NS		<i>p</i> =0.01		<i>p</i> =0.01
Voxel>3.0 mm <sup>3</sup>			0.59±0.24	<i>n</i> =13	0.60±0.16	<i>n</i> =9
Voxel≤3.0 mm <sup>3</sup>			0.74±0.19	<i>n</i> =12	0.76±0.11	<i>n</i> =6
Missing value			0.61±0.22	<i>n</i> =55	0.59±0.12	<i>n</i> =68
		NS		<i>p</i> =0.05		<i>p</i> =0.02
With contrast agents	0.70±0.15	<i>n</i> =8	0.74±0.17	<i>n</i> =7	0.76±0.12	<i>n</i> =7
Without contrast agents	0.55±0.21	<i>n</i> =80	0.61±0.22	<i>n</i> =71	0.59±0.13	<i>n</i> =74
Missing value	0.70±0.19	<i>n</i> =4	0.85±0.14	<i>n</i> =2	0.58±0.08	<i>n</i> =2
	<i>p</i> <0.001		<i>p</i> =0.02		<i>p</i> <0.01	

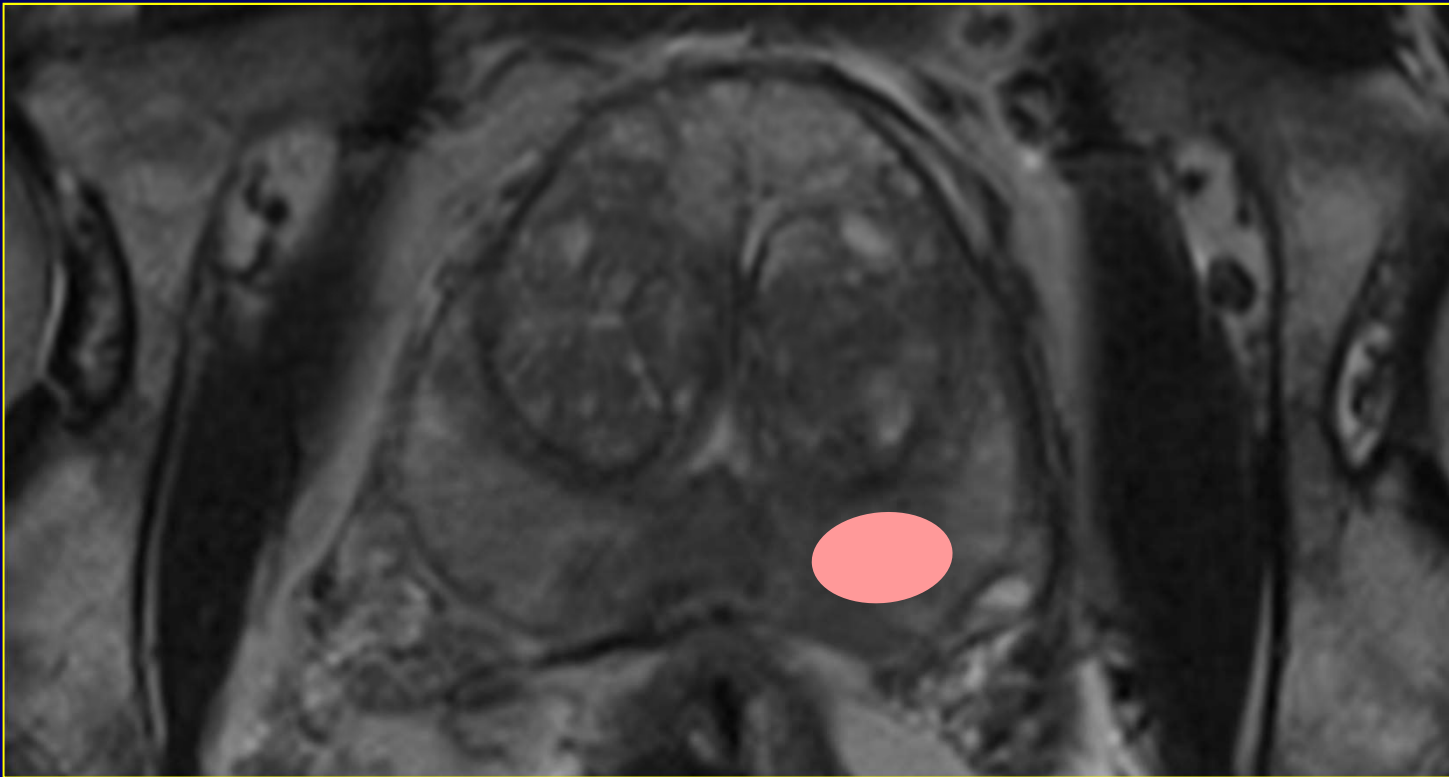
\*Engelbrecht, Eur Radiol 2002;12:2294

**HOW TO SOLVE  
THE PROBLEM?**

# How to solve the problem?

- We need:
  - standardized diagnostic criteria

# Diagnostic criteria

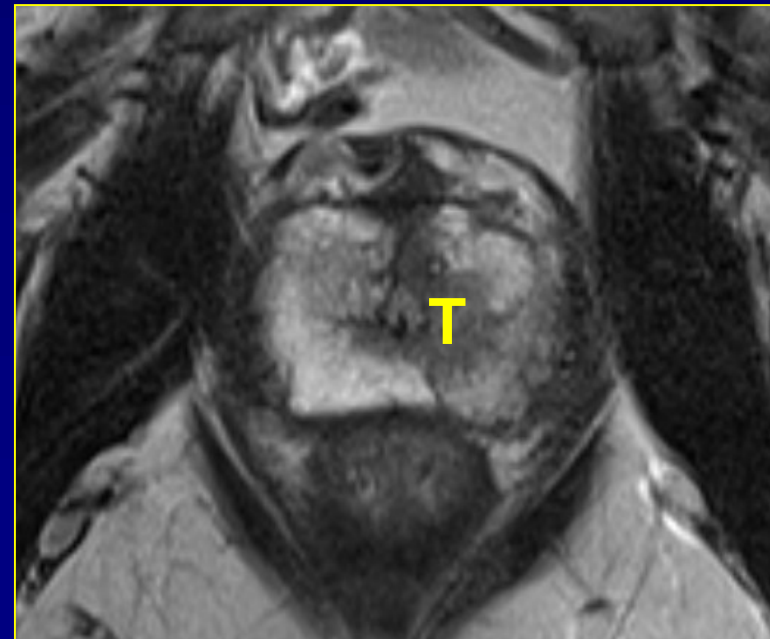


Tumor growth timeline

# Diagnostic criteria

## ECE

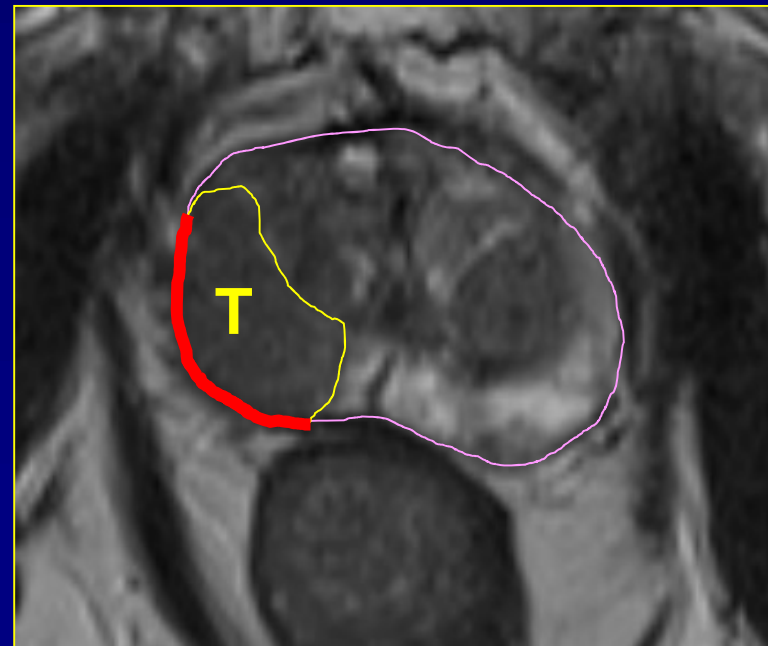
Tumor clearly confined to the prostate



# Diagnostic criteria

## ECE

Broad tumor contact with capsule

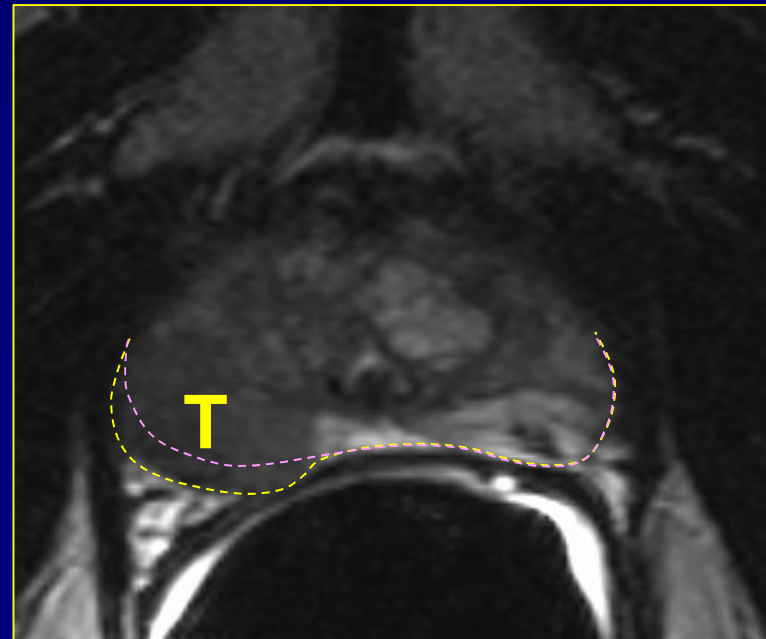


# Diagnostic criteria

## ECE

Broad tumor contact with capsule

Smooth capsular bulging



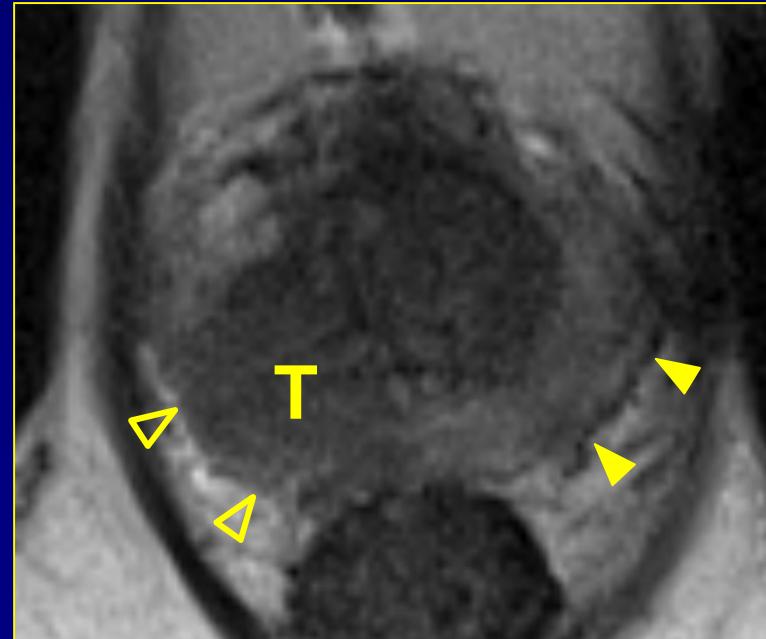
# Diagnostic criteria

## ECE

Broad tumor contact with capsule

Smooth capsular bulging

Capsular SI disruption



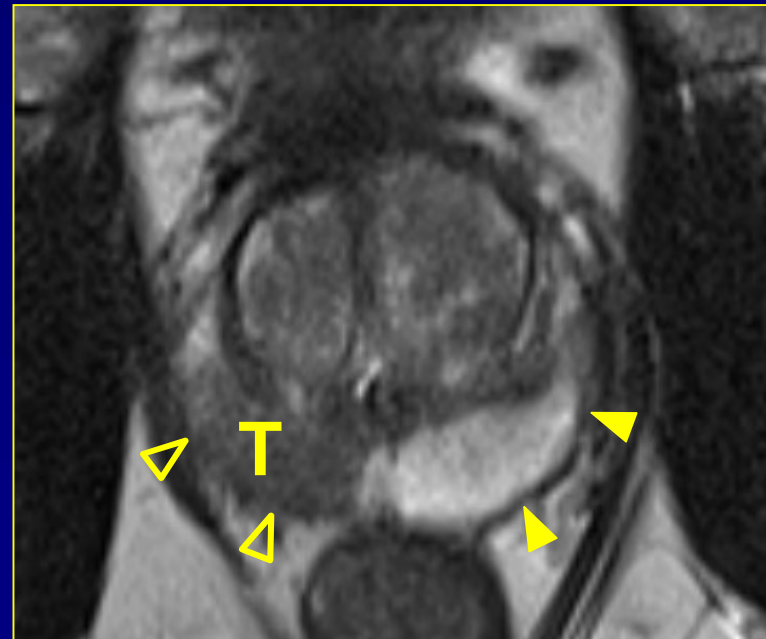# Diagnostic criteria

## ECE

Broad tumor contact with capsule

Smooth capsular bulging

Capsular SI disruption



# Diagnostic criteria

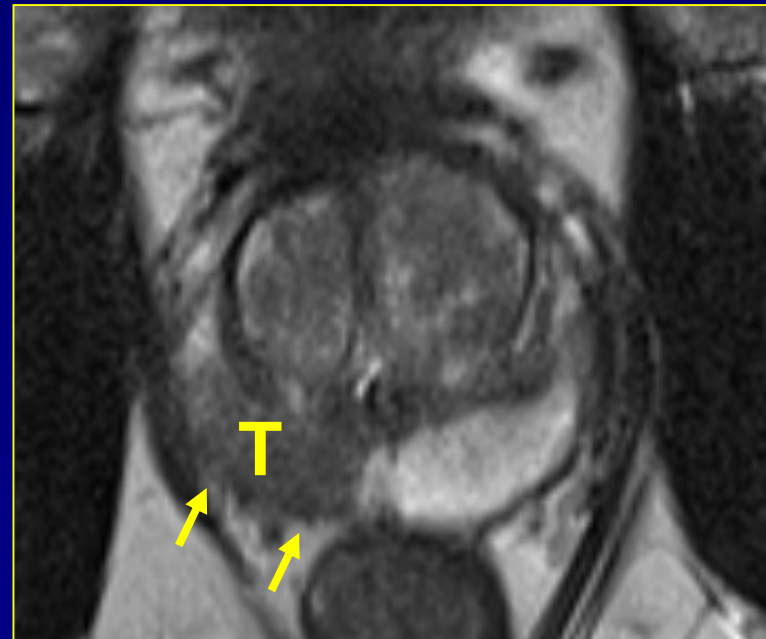
## ECE

Broad tumor contact with capsule

Smooth capsular bulging

Capsular SI disruption

Unsharp margin



# Diagnostic criteria

## ECE

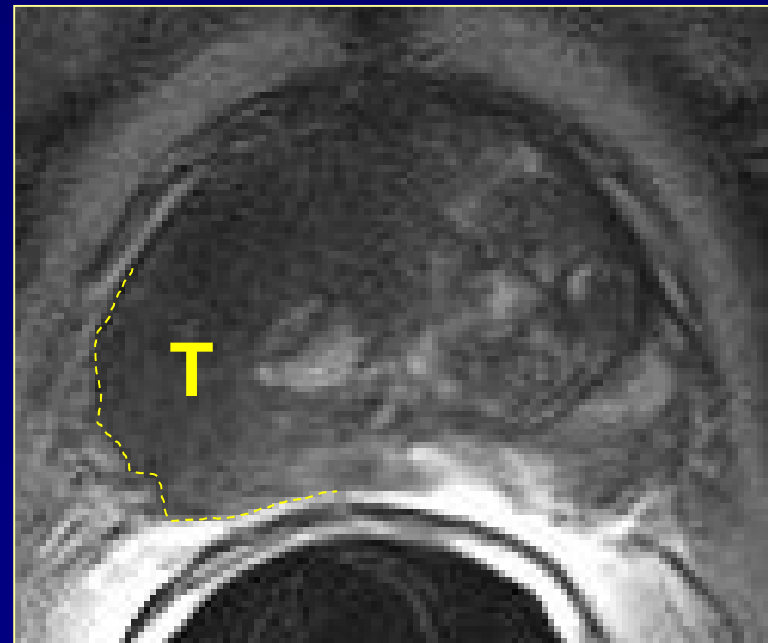
Broad tumor contact with capsule

Smooth capsular bulging

Capsular SI disruption

Unsharp margin

Irregular contour



# Diagnostic criteria

## ECE

Broad tumor contact with capsule

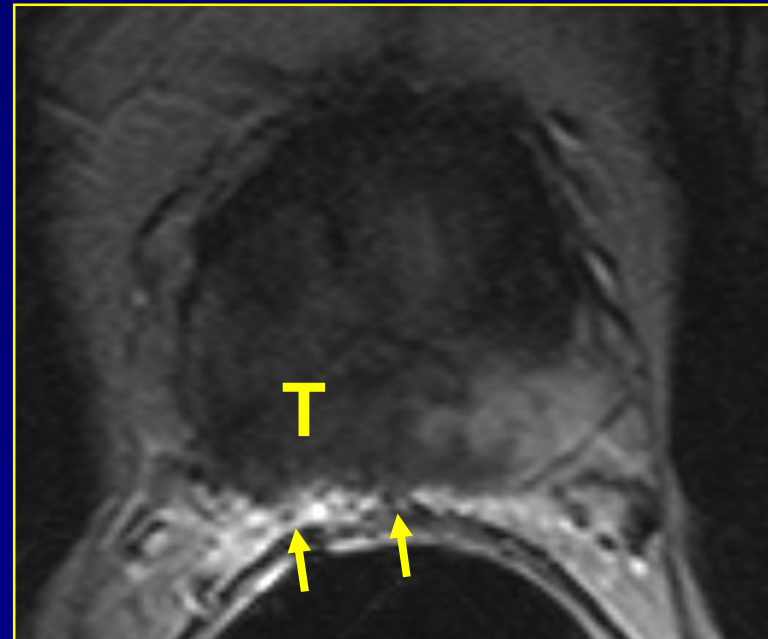
Smooth capsular bulging

Capsular SI disruption

Unsharp margin

Irregular contour

Periprostatic fat infiltration



# Diagnostic criteria

## ECE

Broad tumor contact with capsule

Smooth capsular bulging

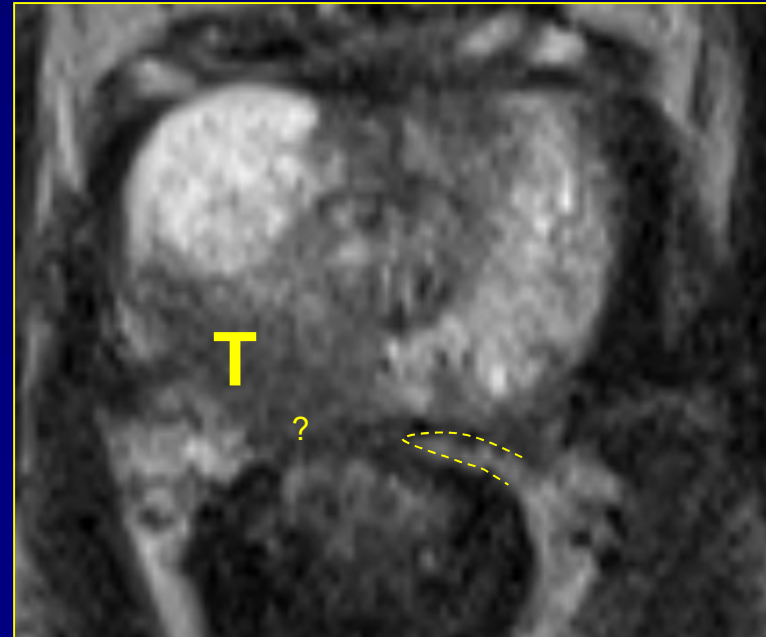Capsular SI disruption

Unsharp margin

Irregular contour

Periprostatic fat infiltration

Obliteration rectoprostatic angle



# Diagnostic criteria

## ECE

Broad tumor contact with capsule

Smooth capsular bulging

Capsular SI disruption

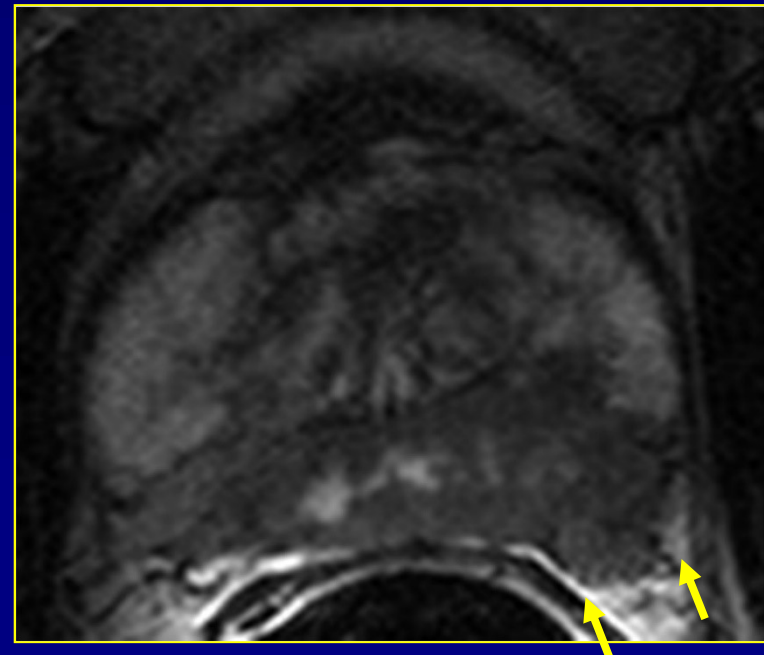Unsharp margin

Irregular contour

Periprostatic fat infiltration

Obliteration rectoprostatic angle

Measurable tumor in periprostatic fat



# Diagnostic criteria

## ECE

Broad tumor contact with capsule

Smooth capsular bulging

Capsular SI disruption

Unsharp margin

Irregular contour

Periprostatic fat infiltration

Obliteration rectoprostatic angle

Measurable tumor in periprostatic fat

# Diagnostic criteria ECE

Intraprostatic

Contact

Minimal ECE

Major ECE

Broad tumor contact with capsule

Smooth capsular bulging

Capsular SI disruption

Unsharp margin

Irregular contour

Periprostatic fat infiltration

Obliteration rectoprostatic angle

Tumor in periprostatic fat

# Diagnostic criteria

## ECE

	PPV	Prevalence
<b>Capsular contact</b>	<b>51,90%</b>	<b>56,90%</b>

# Diagnostic criteria

## ECE

	PPV	Prevalence
<b>Capsular contact</b>	<b>51,90%</b>	<b>56,90%</b>
$\geq 10\text{ mm}$	<i>57,40%</i>	<i>26,50%</i>
$\geq 20\text{ mm}$	<i>81,30%</i>	<i>12,70%</i>

# Diagnostic criteria

## ECE

	PPV	Prevalence
<b>Capsular contact</b>	<b>51,90%</b>	<b>56,90%</b>
$\geq 10\text{ mm}$	<i>57,40%</i>	<i>26,50%</i>
$\geq 20\text{ mm}$	<i>81,30%</i>	<i>12,70%</i>
<b>Capsular disruption</b>	<b>69,00%</b>	<b>18,60%</b>

# Diagnostic criteria

## ECE

	PPV	Prevalence
<b>Capsular contact</b>	<b>51,90%</b>	<b>56,90%</b>
$\geq 10\text{ mm}$	<i>57,40%</i>	<i>26,50%</i>
$\geq 20\text{ mm}$	<i>81,30%</i>	<i>12,70%</i>
<b>Capsular disruption</b>	<b>69,00%</b>	<b>18,60%</b>
<b>Bulging</b>	<b>75,00%</b>	<b>14,70%</b>

# Diagnostic criteria

## ECE

	PPV	Prevalence
<b>Capsular contact</b>	<b>51,90%</b>	<b>56,90%</b>
<i>≥ 10 mm</i>	<i>57,40%</i>	<i>26,50%</i>
<i>≥ 20 mm</i>	<i>81,30%</i>	<i>12,70%</i>
<b>Capsular disruption</b>	<b>69,00%</b>	<b>18,60%</b>
<b>Bulging</b>	<b>75,00%</b>	<b>14,70%</b>
<b>Unsharp prostatic margin</b>	<b>75,00%</b>	<b>11,80%</b>

# Diagnostic criteria

## ECE

	PPV	Prevalence
<b>Capsular contact</b>	<b>51,90%</b>	<b>56,90%</b>
<i>≥ 10 mm</i>	<i>57,40%</i>	<i>26,50%</i>
<i>≥ 20 mm</i>	<i>81,30%</i>	<i>12,70%</i>
<b>Capsular disruption</b>	<b>69,00%</b>	<b>18,60%</b>
<b>Bulging</b>	<b>75,00%</b>	<b>14,70%</b>
<b>Unsharp prostatic margin</b>	<b>75,00%</b>	<b>11,80%</b>
<b>Irregular contour</b>	<b>85,70%</b>	<b>8,80%</b>

# Diagnostic criteria

## ECE

	PPV	Prevalence
<b>Capsular contact</b>	<b>51,90%</b>	<b>56,90%</b>
<i>≥ 10 mm</i>	<i>57,40%</i>	<i>26,50%</i>
<i>≥ 20 mm</i>	<i>81,30%</i>	<i>12,70%</i>
<b>Capsular disruption</b>	<b>69,00%</b>	<b>18,60%</b>
<b>Bulging</b>	<b>75,00%</b>	<b>14,70%</b>
<b>Unsharp prostatic margin</b>	<b>75,00%</b>	<b>11,80%</b>
<b>Irregular contour</b>	<b>85,70%</b>	<b>8,80%</b>
<b>PPF infiltration</b>	<b>87,50%</b>	<b>6,90%</b>

# Diagnostic criteria

## ECE

	PPV	Prevalence
<b>Capsular contact</b>	<b>51,90%</b>	<b>56,90%</b>
<i>≥ 10 mm</i>	<i>57,40%</i>	<i>26,50%</i>
<i>≥ 20 mm</i>	<i>81,30%</i>	<i>12,70%</i>
<b>Capsular disruption</b>	<b>69,00%</b>	<b>18,60%</b>
<b>Bulging</b>	<b>75,00%</b>	<b>14,70%</b>
<b>Unsharp prostatic margin</b>	<b>75,00%</b>	<b>11,80%</b>
<b>Irregular contour</b>	<b>85,70%</b>	<b>8,80%</b>
<b>PPF infiltration</b>	<b>87,50%</b>	<b>6,90%</b>
<b>RPA obliteration</b>	<b>100,00%</b>	<b>2,90%</b>

# Diagnostic criteria

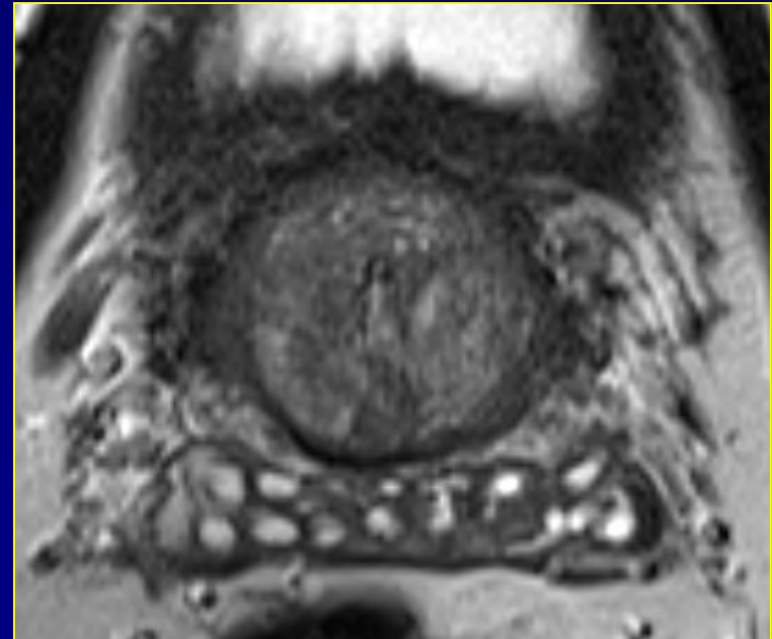
## ECE

	PPV	Prevalence
<b>Capsular contact</b>	<b>51,90%</b>	<b>56,90%</b>
<i>≥ 10 mm</i>	<i>57,40%</i>	<i>26,50%</i>
<i>≥ 20 mm</i>	<i>81,30%</i>	<i>12,70%</i>
<b>Capsular disruption</b>	<b>69,00%</b>	<b>18,60%</b>
<b>Bulging</b>	<b>75,00%</b>	<b>14,70%</b>
<b>Unsharp prostatic margin</b>	<b>75,00%</b>	<b>11,80%</b>
<b>Irregular contour</b>	<b>85,70%</b>	<b>8,80%</b>
<b>PPF infiltration</b>	<b>87,50%</b>	<b>6,90%</b>
<b>RPA obliteration</b>	<b>100,00%</b>	<b>2,90%</b>
<b>Periprostatic mass</b>	<b>100,00%</b>	<b>2,90%</b>

# Diagnostic criteria

## SVI

Diffuse wall thickening

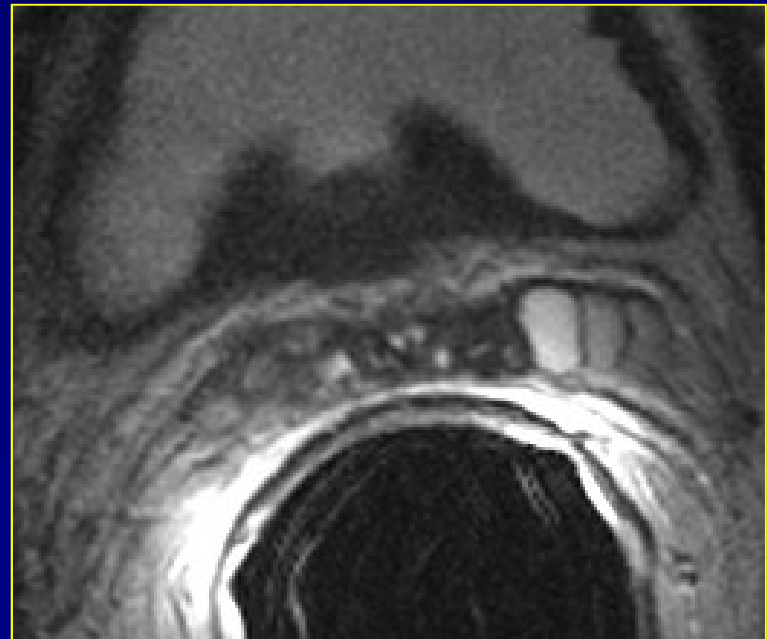


# Diagnostic criteria

## SVI

Diffuse wall thickening

Focal wall thickening

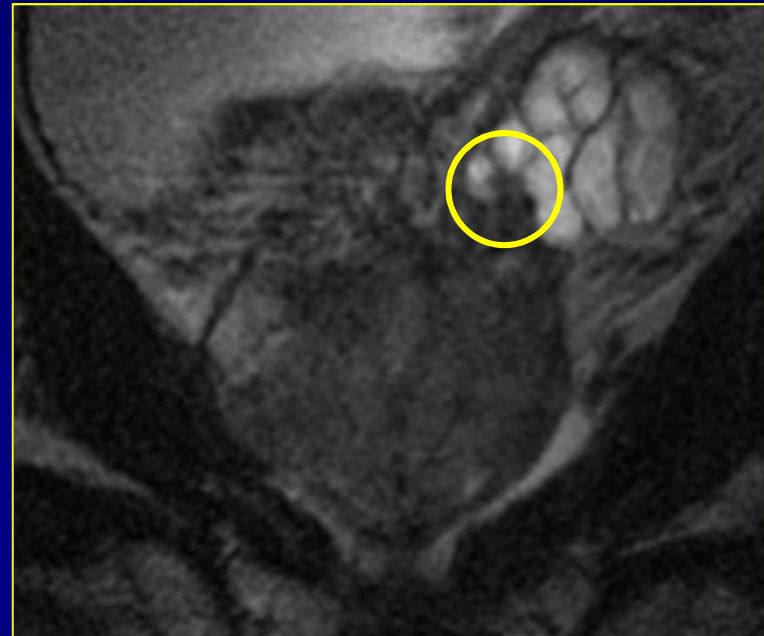

# Diagnostic criteria

## SVI

Diffuse wall thickening

Focal wall thickening



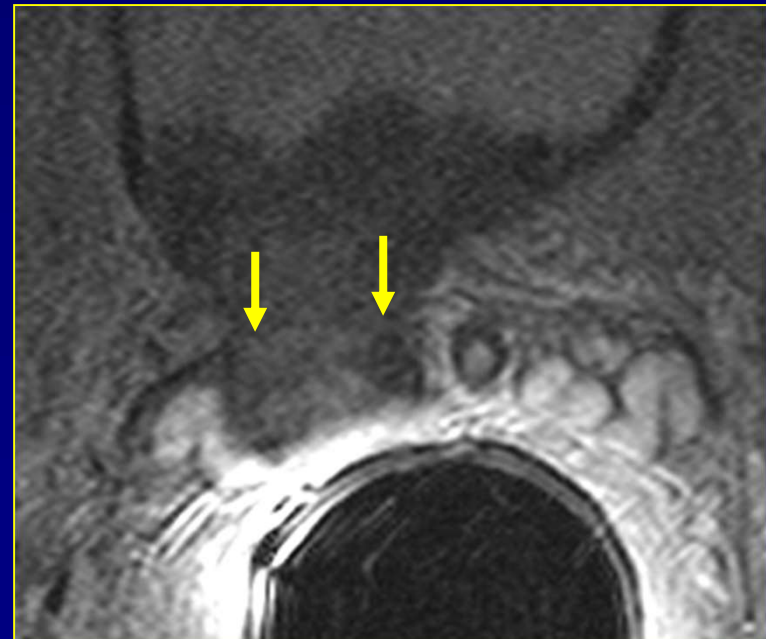
# Diagnostic criteria

## SVI

Diffuse wall thickening

Focal wall thickening

Intraluminal mass



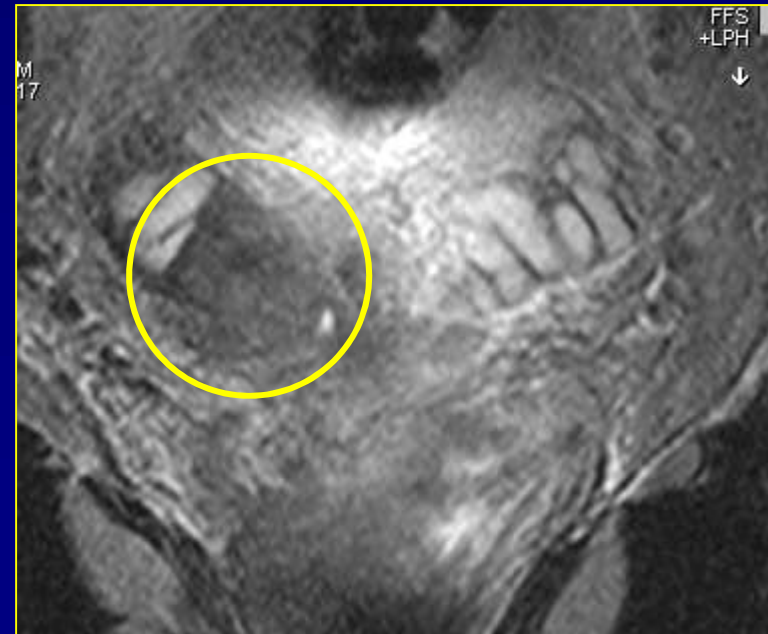
# Diagnostic criteria

## SVI

Diffuse wall thickening

Focal wall thickening

Intraluminal mass



# Diagnostic criteria

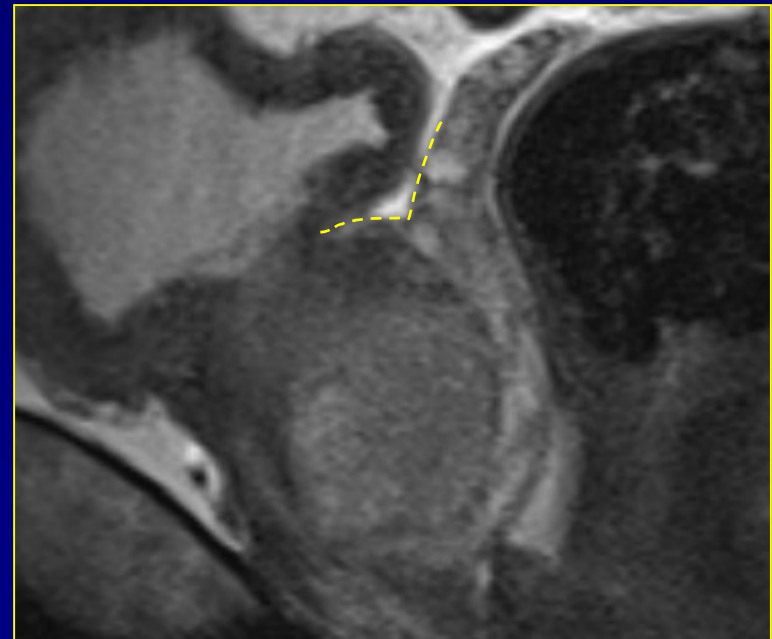
## SVI

Diffuse wall thickening

Focal wall thickening

Intraluminal mass

Obliteration of prostatovesicular angle



# Diagnostic criteria

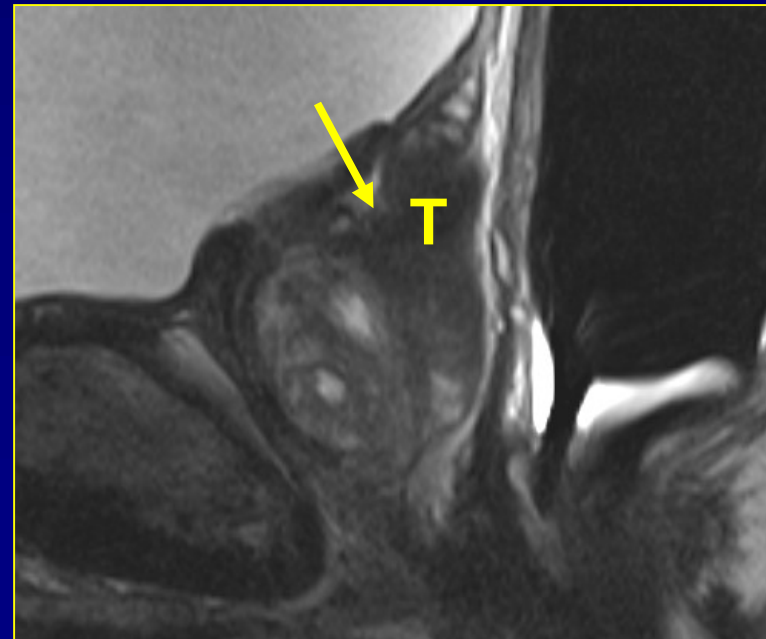## SVI

Diffuse wall thickening

Focal wall thickening

Intraluminal mass

Obliteration of prostatovesicular angle



# Diagnostic criteria

## SVI

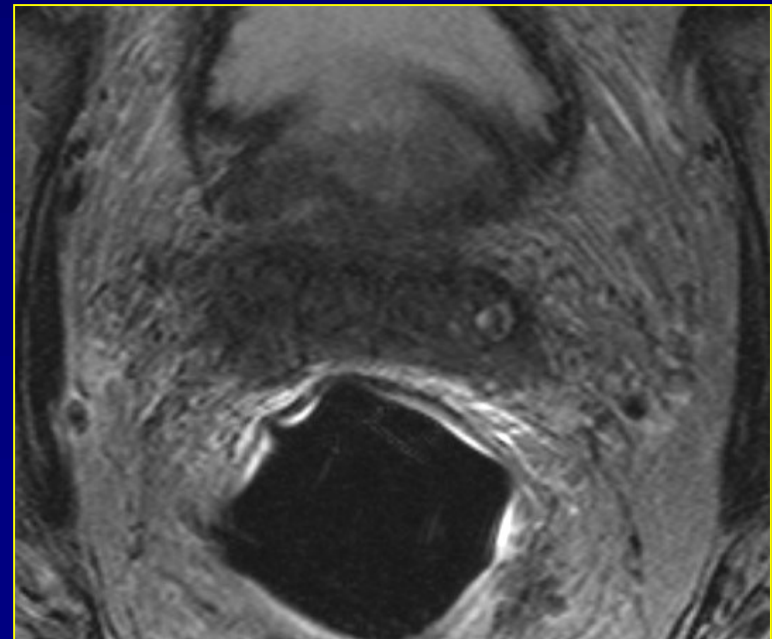
Diffuse wall thickening

Focal wall thickening

Intraluminal mass

Obliteration of prostatovesicular angle

Destruction



# How to solve the problem?

- We need:
  - standardized diagnostic criteria
  - standardized technical parameters



## ESUR prostate MR guidelines 2012

Jelle O. Barentsz • Jonathan Richenberg •  
Richard Clements • Peter Choyke • Sadhna Verma •  
Geert Villeirs • Olivier Rouviere • Vibeke Logager •  
Jurgen J. Fütterer

Received: 16 October 2011 / Revised: 23 November 2011 / Accepted: 2 December 2011 / Published online: 10 February 2012  
© The Author(s) 2012. This article is published with open access at Springerlink.com

**Abstract** The aim was to develop clinical guidelines for multi-parametric MRI of the prostate by a group of prostate MRI experts from the European Society of Urogenital Radiology (ESUR), based on literature evidence and consensus expert opinion. True evidence-based guidelines could not be formulated, but a compromise, reflected by “minimal” and

### *Key Points*

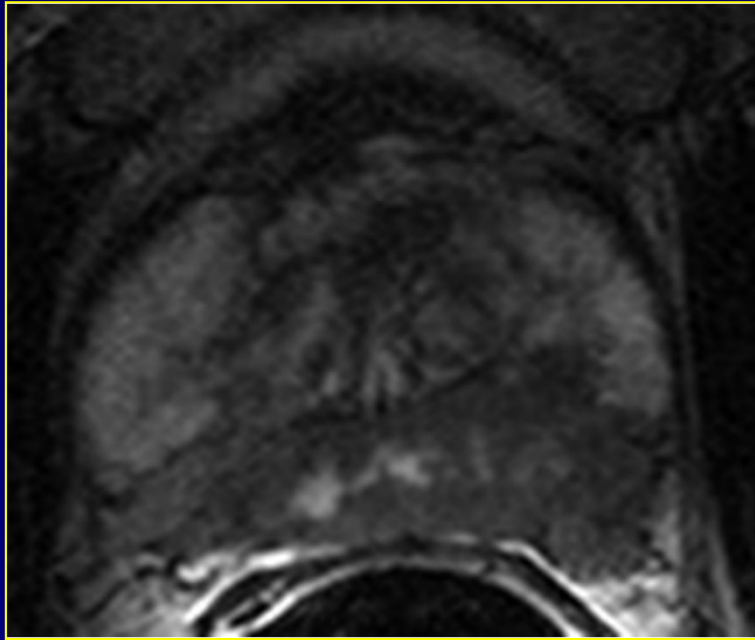
- *This report provides guidelines for magnetic resonance imaging (MRI) in prostate cancer.*
- *Clinical indications, and minimal and optimal imaging acquisition protocols are provided.*
- *A structured reporting system (PI-RADS) is described.*

# Technical parameters

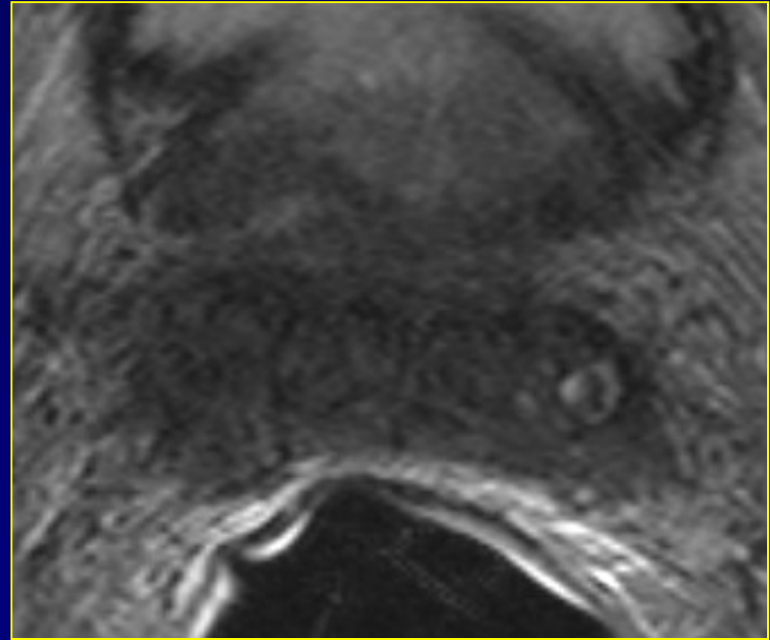
- Optimal T2-weighted MRI
  - thin slices (preferably 3 mm)
  - high in-plane resolution (preferably  $512^2$ ) and small field of view (preferably  $0.3 \text{ mm}^2$ )
  - transverse images perpendicular to posterior prostate margin
- Functional imaging?

# **DIAGNOSTIC THRESHOLD**

# Diagnostic threshold

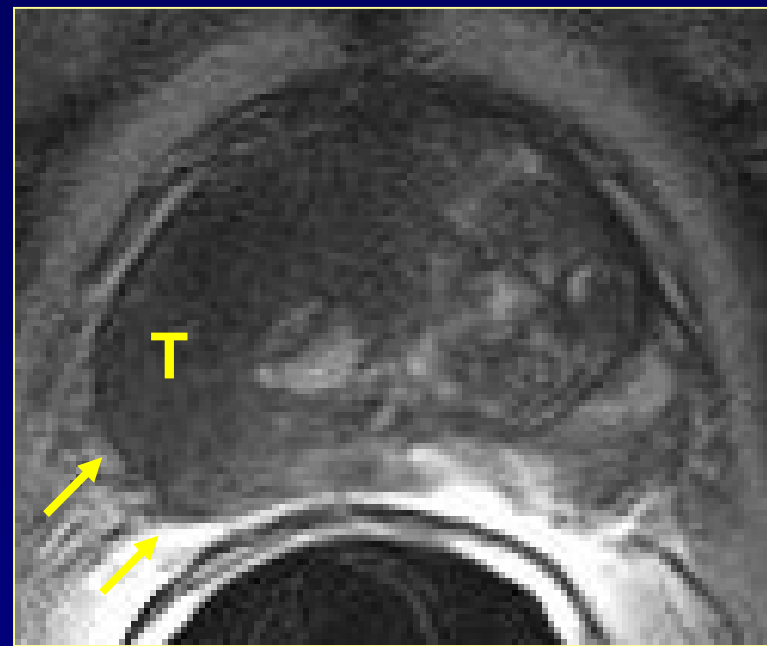
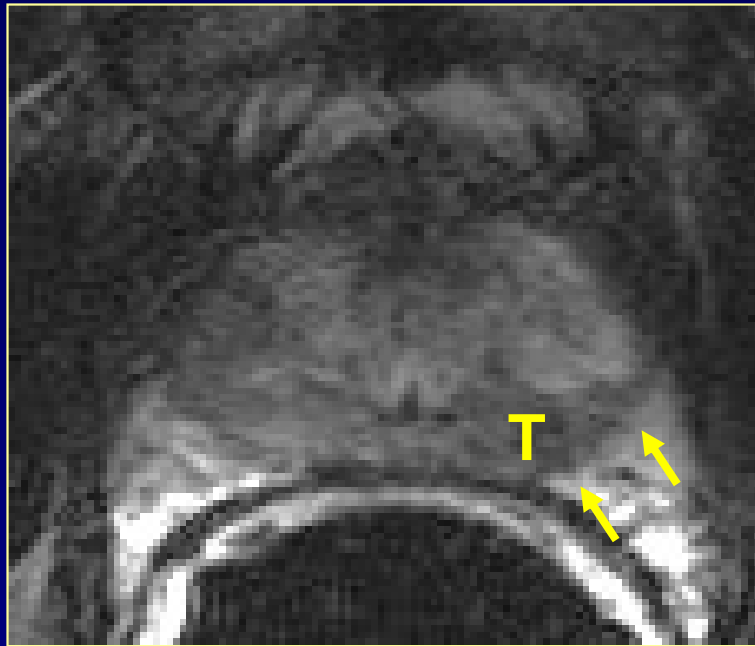


iT3a



iT3b

# Diagnostic threshold



Slight capsular irregularity  
Slight capsular undulation

# Diagnostic threshold

Intraprostatic

Contact

Minimal ECE

Gross ECE

Broad tumor contact with capsule

Smooth capsular bulging

Capsular SI disruption

Unsharp margin

Irregular contour

Periprostatic fat infiltration

Obliteration rectoprostatic angle

Tumor in periprostatic fat

# Diagnostic threshold

Intraprostatic

Contact

Minimal ECE

Gross ECE

Broad tumor contact with capsule

Smooth capsular bulging

Capsular SI disruption

Unsharp margin

# Diagnostic threshold

- A doubtful MRI should not change the therapy plan
- Talk to the surgeon:
  - active surveillance good option?
  - broader margin at site of potential ECE → more R0!

# TAKE HOME MESSAGES

# Take home messages

- For diagnosis
  - do mpMRI of the prostate
    - standardized according to PI-RADSv2
      - technical requirements
      - reporting
    - results in
      - less biopsies overall
      - detection of more significant cancers
      - detection of less insignificant cancers

# Take home messages

- For staging
  - use MRI of the prostate
    - assessment of
      - capsular perforation
      - seminal vesicle invasion
    - talk to the surgeon!

[Geert.Villeirs@UGent.be](mailto:Geert.Villeirs@UGent.be)



**Ghent University Hospital  
Belgium**



