

Advanced
management of severe
traumatic head
injuries; ICP
monitoring, DECRA &
other modalities

JR OUMA

*MB ChB, MMed
(Wits)(Neurosurg),
FCS(SA)Neurosurg, FACS,
FRCS England (Neurosurg)*

University of the
Witwatersrand,
Johannesburg & CH
Baragwaanth Academic
Hospital, Soweto

AFRICA HEALTH 2019

Tuesday 28th May 2019

Gallagher Convention
Centre

Defining severe traumatic brain injury

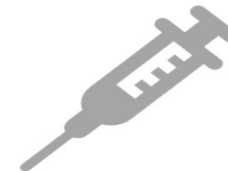

Primary injury

Damage done at the instant of injury

Designated by immediate post resuscitation GCS
< 8/15

Period of post traumatic amnesia also denotes it
PTA > 24 hours



Secondary injury

Delayed damage on account of abnormalities in
A/B/C/G etc

Local and systemic factors

Predicted by CT scans and systemic parameters

Why advanced management of severe TBI?

Conventional methods of treatment have hit a plateau

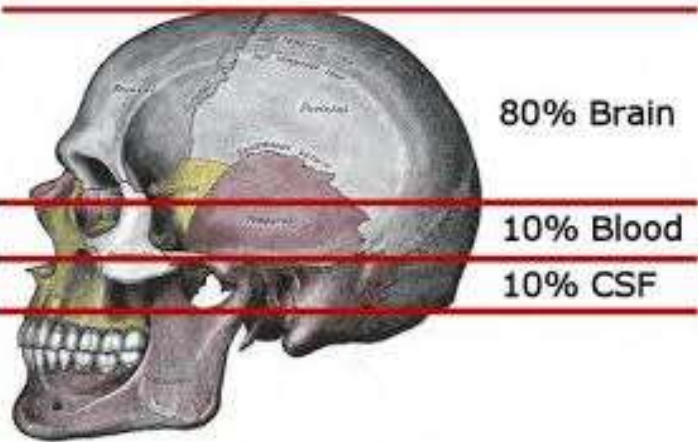
Need to go the extra mile to salvage brain and improve outcomes

The main issue at hand is raised intracranial pressure and cerebral under perfusion, with vascular & metabolic derangements

Key concepts

Cerebral
perfusion

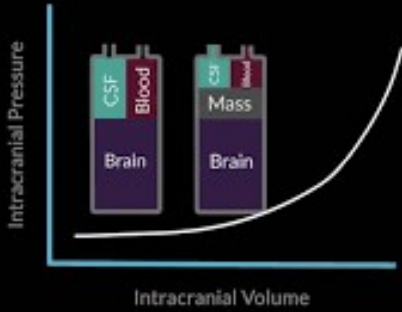
Cerebral
metabolism



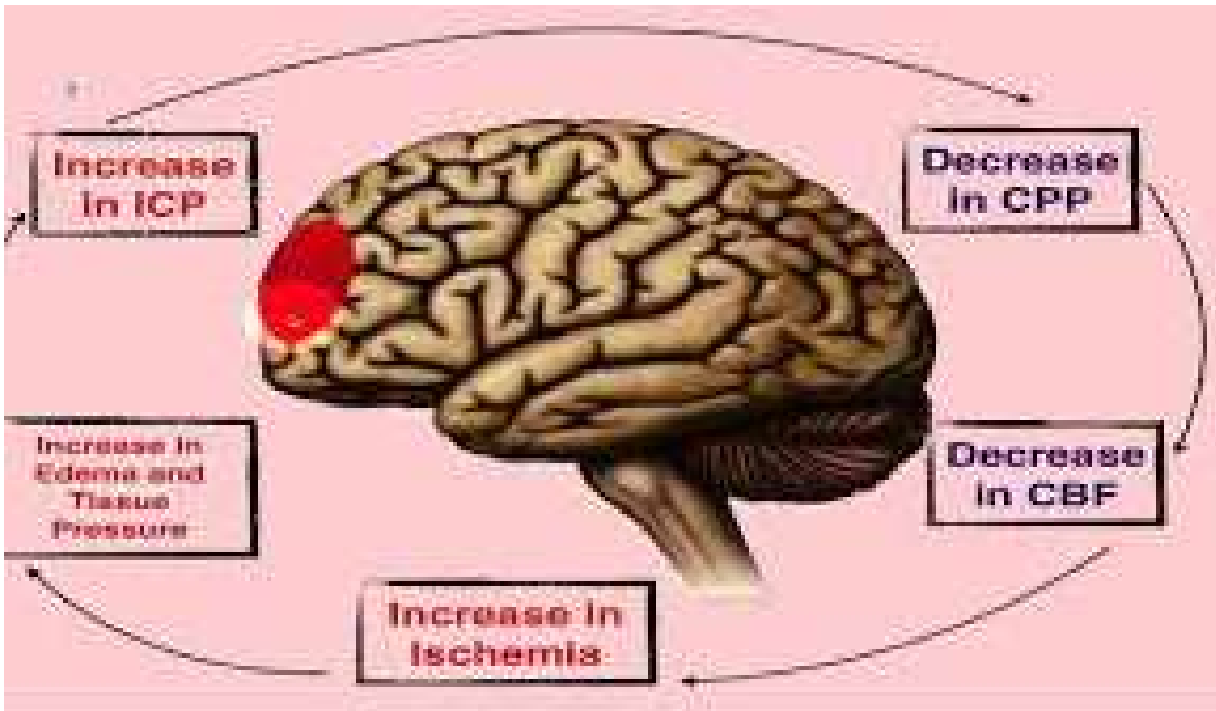
The Monroe - Kellie Doctrine

- Fixed skull volume
- Three primary constituents
- Increased volume in any one must be matched by decreased volume of one or more of the other two or else there will be an increase in intracranial pressure

Monro-Kellie Doctrine



OP



Relationship between intracranial pressure, cerebral perfusion & cerebral blood volumes

- Cerebral perfusion pressure (CPP) = $MAP - ICP$
- Cerebral blood flow (CBF) = MAP/CVR
- Factors affecting CBF include
 - Local pressure
 - Local metabolites
 - Local vasoreactivity



This Photo by Unknown Author is licensed under [CC BY-NC-ND](#)

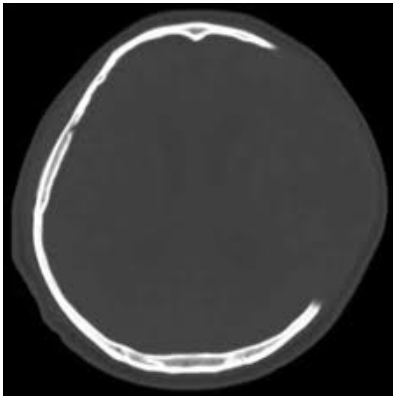
The concept of brain umbra and penumbra

- The umbra may be lost
- The penumbra may be salvageable

Advanced techniques in severe TBI

Surgical

- DECRA (Decompressive craniectomy)



Multi-modality Monitoring

- ICP monitoring
- Brain Oxygen tension monitoring
- Brain temperature monitoring
- Cerebral microdialysis
 - L/P ratios
- Regional cerebral blood flow
- EEG monitoring

DECRA



Basic premise is to create space for the swollen brain to expand into, thus reducing intracranial pressure and hopefully salvaging brain



Akin to fasciotomy or decompressive laparotomy surgery



Wide craniotomy/craniectomy of the affected area



Duraplasty



Controversial


Timing?

Increased survival but of impaired individuals

The Current Status of Decompressive Craniectomy in Traumatic Brain Injury

Authors

[Authors and affiliations](#)

Angelos G. Kolias , Edoardo Viaroli, Andres M. Rubiano, Hadie Adams, Tariq Khan, Deepak Gupta, Amos Adeleye,

Corrado Iaccarino, Franco Servadei, Bhagavatula Indira Devi, Peter J. Hutchinson

[Open Access](#) | Traumatic Brain Injury (A Valadka, Section Editor)

First Online: 01 September 2018

53

Shares

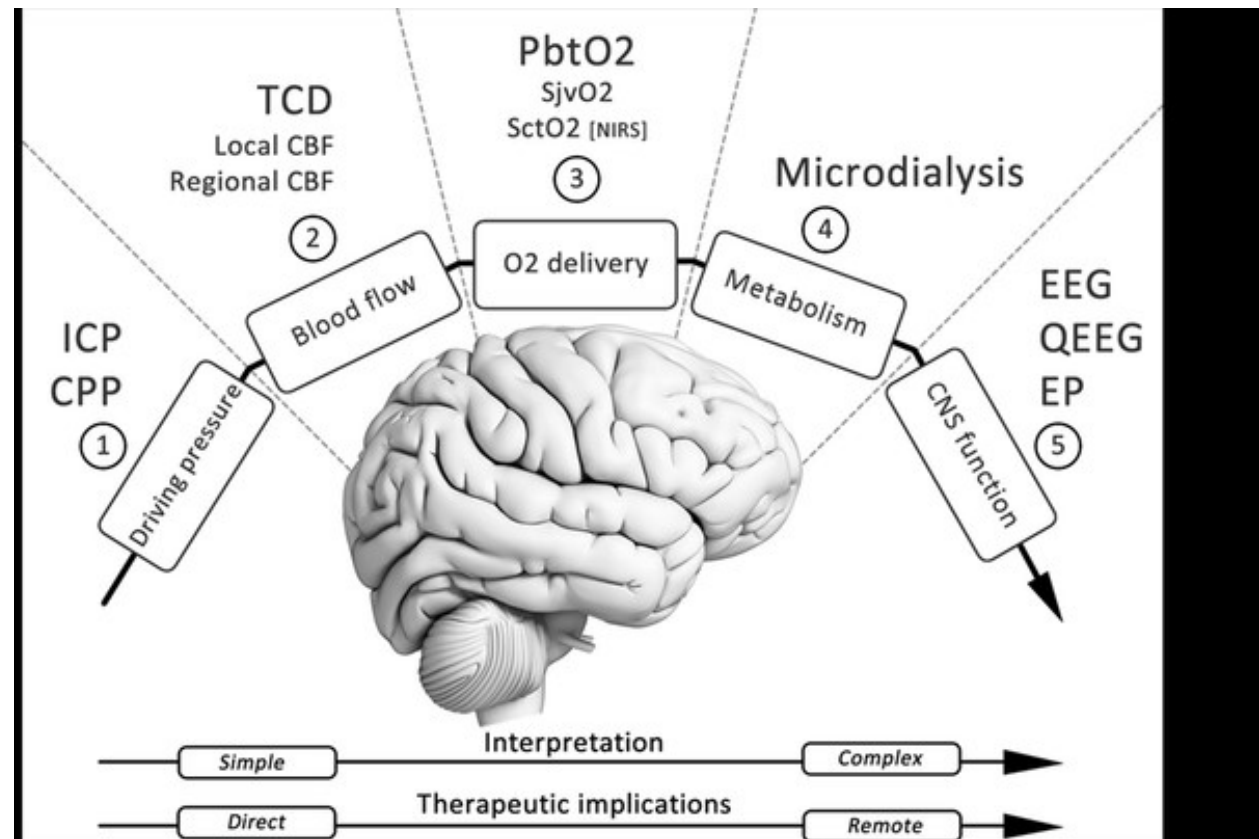
2.2k

Downloads

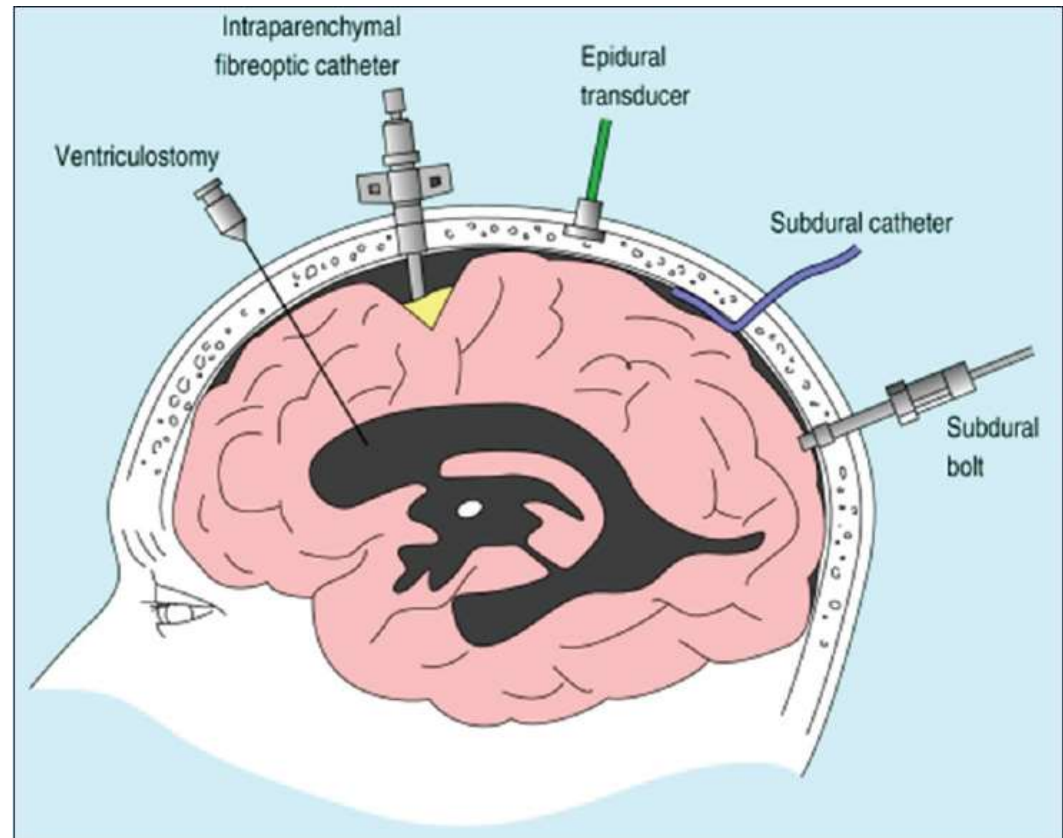
Conclusions

Several TBI subtypes associated with brain swelling and/or raised ICP can be managed by DC. However, current evidence from multicenter clinical trials suggests that (1) early neuroprotective bifrontal DC for mild to moderate intracranial hypertension is not superior to medical management for patients with diffuse TBI, and (2) unilateral or bifrontal DC used as a last-tier therapy for patients with severe, sustained, and refractory posttraumatic intracranial hypertension leads to a substantial mortality reduction but increases disability (both lower and upper severe disability) compared to medical management.

Multi-modality
brain
monitoring



Monitors



In conclusion

